




Hepatoyeyunoanastomosis Laparoscópica. Experiencia inicial en 21 casos consecutivos

Laparoscopic Hepaticojejunostomy. Initial experience in 21 consecutive cases

Hepatojejunostomia laparoscópica. Experiência inicial em 21 casos consecutivos

Maisa Alkhwani¹, Mohammed Nasser¹, Ahmed Bayazeed²,
 Esraa Alshehrani³, Christian Janikow⁴

DATOS DE AUTORES

1. General Surgeon Consultant. King Fahad General Hospital, Jeddah, KSA.
2. General Surgeon Specialist. King Fahad General Hospital, Jeddah, KSA.
3. Resident in General Surgery. King Fahad General Hospital, Jeddah, KSA.
4. Hepatobiliary Consultant. King Fahad General Hospital, Jeddah, KSA. Contact mail: janikowchristian@icloud.com

Recibido: 2024-04-25 **Aceptado:** 2024-09-02

doi DOI: <http://dx.doi.org/10.31053/1853.0605.v81.n4.44694>



<https://creativecommons.org/licenses/by-nc/4.0/>

©Universidad Nacional de Córdoba



Hepatoyeyunoanastomosis Laparoscópica. Experiencia inicial en 21 casos consecutivos

CONCEPTOS CLAVE.

¿Qué se sabe sobre el tema?

Laparoscopy Hepaticojejunostomy is an advanced surgical procedure under experienced hepatobiliary surgeons. It's indicated in a wide range of pathologies of the biliary system. Until now, the minimally invasive approach is not the gold standard..

¿Qué aporta este trabajo?

Communicate to the scientific field what is being developed in a general surgery department in Jeddah, Saudi Arabia; under the guidance of a hepatobiliary surgeon from Argentina.

Divulgación

We describe our experience with laparoscopic hepaticojejunostomy in 21 consecutive cases. The steps of the surgical technique and post-operative complications are described. A brief update on laparoscopic hepaticojejunostomy surgery is mentioned



Hepaticoyeyunoanastomosis Laparoscópica. Experiencia inicial en 21 casos consecutivos

Resumen

Palabras clave:

hepaticoyeyunostomía laparoscópica;
laparoscopía avanzada; hepatobiliar

Introducción: la hepaticoyeyunostomía laparoscópica es un procedimiento complejo con distintas indicaciones. Aun así, el abordaje laparoscópico no es aún el gold-standard, pero es bien conocido por sus beneficios en cuanto a la recuperación postoperatoria. Presentamos nuestra experiencia en 21 casos consecutivos de hepaticoyeyunostomía laparoscópica realizada en el Hospital General King Fahad en Jeddah. **Métodos:** se realizaron 21 hepaticoyeyunostomías laparoscópicas consecutivas desde enero de 2022 hasta diciembre de 2023. **Sexo:** 10 hombres y 11 mujeres, edad promedio 46 años. La indicación más común fue por múltiples cálculos en el colédoco. **Resultados:** tiempo quirúrgico promedio: 180 minutos, pérdida sanguínea promedio: 168 ml. Según la clasificación de Clavien-Dindo registramos un tipo de complicación: 3A. El promedio de días de internación fue de 5,5; no se informó mortalidad. **Conclusión:** Creemos que el éxito de la hepaticoyeyunostomía laparoscópica está relacionado con un excelente conocimiento del sistema biliar y con cirujanos experimentados en procedimientos laparoscópicos avanzados.



Laparoscopic Hepaticojejunostomy. Initial experience in 21 consecutive cases

Abstract

Keywords:

laparoscopic
hepaticojejunostomy;
advanced laparoscopy;
hepatobiliary

Introduction: laparoscopic hepaticojejunostomy is a complex procedure indicated for different pathologies. Still, the laparoscopic approach is not the gold standard, but it is well known for its benefits regarding post operative recovery. We present our experience in 21 consecutive cases of laparoscopic hepaticojejunostomy done at King Fahad General Hospital in Jeddah. Methods: 21 consecutives laparoscopic hepaticojejunostomies were done from January 2022 to December 2023. Gender: 10 male and 11 female, average age 46 years. The most common indication is due to multiple common bile duct stones. Results: average surgical time: 180 minutes, average blood loss: 168 ml. According to Clavien-Dindo's classification, we recorded one complication type: 3A. Average discharge days were 5.5; no mortality was reported. Conclusion: We believe that the success of laparoscopic hepaticojejunostomy is related to excellent knowledge of the biliary system and an experienced surgeon in advanced laparoscopic procedures.



Hepatojejunostomia laparoscópica. Experiência inicial em 21 casos consecutivos

Resumo

Palavras-chave:

hepaticojejunostomia
laparoscópica;
laparoscopia avançada;
hepatobiliar

Introdução: a hepaticojejunostomia laparoscópica é um procedimento complexo e com diversas indicações. Mesmo assim, a abordagem laparoscópica ainda não é o padrão-ouro, mas é bem conhecida pelos seus benefícios em termos de recuperação pós-operatória. Apresentamos nossa experiência em 21 casos consecutivos de hepaticojejunostomia laparoscópica realizados no Hospital Geral King Fahad em Jeddah. Métodos: Foram realizadas 21 hepaticojejunostomias laparoscópicas consecutivas de janeiro de 2022 a dezembro de 2023. Sexo: 10 homens e 11 mulheres, idade média de 46 anos. A indicação mais comum foram múltiplos cálculos no ducto biliar comum. Resultados: tempo cirúrgico médio: 180 minutos, perda sanguínea média: 168 ml. Segundo a classificação de Clavien-Dindo registramos um tipo de complicação: 3A. A média de dias de internação foi de 5,5; nenhuma mortalidade foi relatada. Conclusão: Acreditamos que o sucesso da hepaticojejunostomia laparoscópica está relacionado ao excelente conhecimento do sistema biliar e à experiência de cirurgiões em procedimentos laparoscópicos avançados.



Introduction

The benefits of minimally invasive procedures are well known in the surgical field. Hepaticojejunostomy (HJ) is a complex procedure used as a rescue option with a range of indications that include choledochal cyst, Mirizzi syndrome type II, cholangiocarcinoma allocated at the mid Common Bile Duct (CBD), palliative drainage of the CBD in advance pancreatic cancer, CBD injury, resolution of multiple CBD stones in sickle anemia patients, and gallbladder cancer invading the CBD⁽¹⁾.

Since Prof. Dr. Pablo Mirizzi introduced the intraoperative cholangiogram in the surgical theatre, knowledge and understanding of the physiopathology and anatomy of the CBD have skyrocketed⁽²⁾⁽³⁾⁽⁴⁾. Indications of hepaticojejunostomy were based on the pathology findings. According to Mirizzi, in benign disease, a dilated CBD up to 2 cm with multiple stones and a thickened wall is a clear indication for hepaticojejunostomy, especially in young patients⁽⁵⁾.

We present our experience of the first 21 consecutive cases of Laparoscopic Hepaticojejunostomy (LH) at the surgical department of King Fahad General Hospital in Jeddah, Saudi Arabia.

Case presentation

Methods

From January 2022 to December 2023, data from all patients that underwent LH at the General Surgery department of King Fahad General Hospital in Jeddah, Saudi Arabia, were collected.

The present study was granted under IRB approval number: A01887 according to KAST (GCP) regulations.

Patients included in the study met the following surgical indications for HJ:

- Choledochal cyst Todani type I and IVa/b (in those cases a CBD resection was added).
- Bile duct injury that needs HJ as treatment.
- Cholangiocarcinoma of the mid CBD in which cases also a resection of it was added.
- Multiple CBD stones with previous ERCP attempts to clear them but failed.
- Mirizzi syndrome type IIC.
- Benign stenosis of the CBD with failed attempts of minimal invasive procedures management.
- Palliative management of periampullary malignancy with failed attempts of minimal invasive procedures management.

Design

Retrospective with prospective data collection.

Relevant key points of the surgical technique included: patient in supine position and reverse Trendelenburg; surgeon on the left side; and 4 ports.

(one 10mm for the scope, one 12mm for endo-GIA, and two 5mm) with the same distribution as laparoscopic cholecystectomy. The CBD was transected with a cold knife (endo scissors); in those patients with CBD injuries, the bile duct was dissected further and transected at a safe level to avoid the influence of the thermal injury. The hepaticojejunostomy was performed with interrupted stitches with PDS 4-0. The Roux-Y limb was done at 60cm with an endo-GIA blue load and secured with interrupted stitches of Vicryl 3-0. In all cases, the Roux-Y limb was ante-colic. No conversion to an open procedure was needed. **(fig1) (fig 2)**

The follow up was done in short and long term. The short term was done within the first two months, and the long term at month 3, 6, 12 and 24 post operation. The morbidity and mortality were classified according to Clavien-Dindo's classification.



Statistics analysis:

data collection and statistics analysis were done in excel sheets.

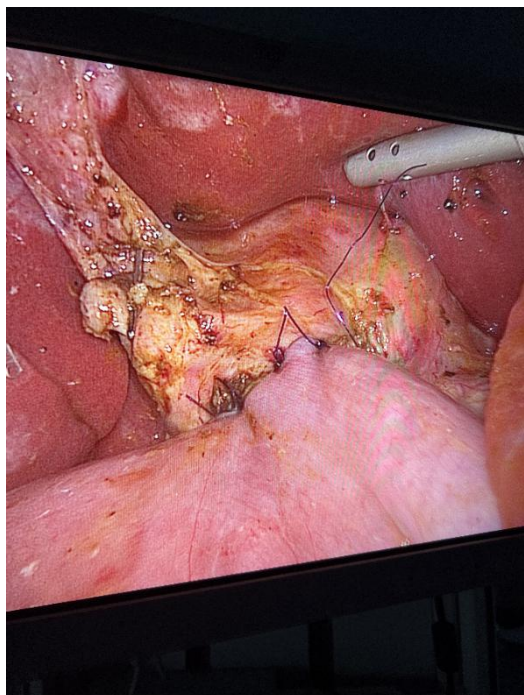


Figure 1: Hepaticojejunostomy

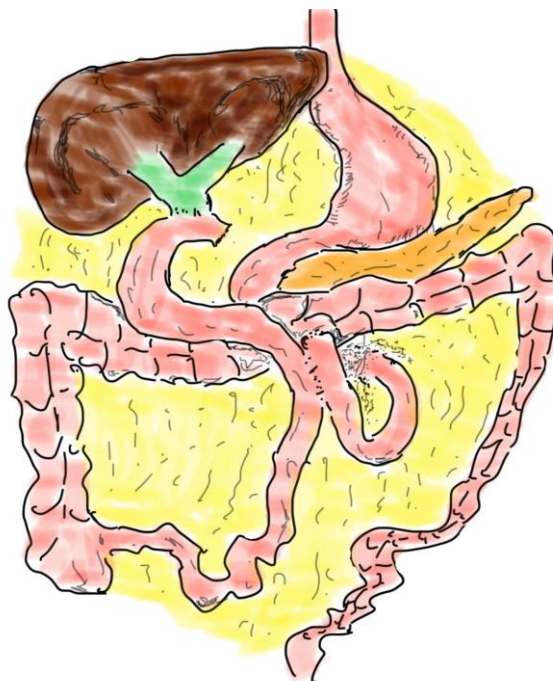


Figure 2: Ante colic anastomosis

Results

A total of 21 patients were collected from the data base. Ten patients were male and 11 females, with an average age of 46.23 +/- 16.74.

Indications for HJ included:

- a) 12 patients with multiple CBD stones and failed attempts of ERCP clearance (average attempts 3), 5 of them had sickle anemia, 2 of them where reintervention due to recurrent CBD stones (they received years back CBD exploration by open approach and multiple ERCP attempts to clear the stones).
- b) 3 patients with CBD injury.
- c) 1 patient with Mirizzi Syndrome type IIC.
- d) 1 patient received palliative HJ due to advanced pancreatic cancer.
- e) 2 patients had Choledochal cyst type I and type IV.
- f) 1 patient had Cholangiocarcinoma of the common hepatic duct.
- g) 1 patient had stenosis of a previous HJ. (Table 1)



Table 1: Diagnosis for hepaticojejunostomy in our series

Diagnosis	Number and % of patients
Multiple CBD stones in sickle anemia *	5 (23%)
Primary multiple CBD stones*	5 (23%)
Secondary multiple CBD stones **	2 (9%)
CBD injury	3 (14%)
Mirizzi Syndrome	1 (4%)
Advanced pancreatic cancer	1 (4%)
Choledochal cyst	2 (9%)
Cholangiocarcinoma of the CBD	1 (4%)
Stenosis of previous HJ	1 (4%)

CBD: Common Bile Duct

HJ: Hepaticojejunostomy

* With multiple failed ERCP attempts to clear the stones.

** With history of CBD exploration by open approach.

The average operation time was 180 minutes, with a maximum of 220 minutes and a minimum of 155 minutes. Blood loss was minimal, with an average of 168 ml, a maximum of 230 ml and a minimum of 100 ml. In all cases, we placed a drain for post operation follow-up.

Post -operation complications included, in one case, a leak with the development of a bilioma that was treated by percutaneous drainage. This patient had a previous history of breast cancer treated with radiotherapy and chemotherapy, conditions that are well known as risk factors for leaks and wound complications ⁽⁶⁾. Two patients developed vomiting that required repeated doses of anti-emetic medications. Wound infections were found in two patients at the level of the umbilical port. (**Table 2**). According to the Clavien-Dindo classification, one case was type 3a, and the remaining 20 patients were type 1.

The average discharge time was 5.5 days +/- 7.5 days, with a minimum of 1 day and a maximum of 35 days; the median was 3 days; and the mode 1 day.

No mortality was reported. The short-term follow-up of 1 year showed one case of stenosis that was treated after unsuccessful balloon dilatation with Laparoscopic redu-Hepaticojejunostomy. The long term follow up will be done after 2 years for the complete series.

Table 2: Post -operative hepaticojejunostomy complications in the series.

Complications post op	Number of cases and %
Bilioma	1 (4,7%)
Vomiting	2 (9,5%)
Wound infection	2 (9,5%)



Discussion

Hepaticojejunostomy is an available option for different types of disease of the biliary tree⁽⁵⁾⁽⁷⁾. There is a clear indication in those cases of choledochal cyst Todani type I and IV, on which CBD resection is added. In cases of CBD injuries, depending on the type of injury, HJ is also indicated. In young patients with multiple CBD stones, especially in sickle anemia cases, the HJ can end the multiple attempts of ERCP for stone removal. Elderly patients with similar conditions might benefit from Choledochal duodenum anastomosis, but with the risk of recurrent ascending cholangitis⁽⁸⁾. In cholangiocarcinoma at the level of the CHD, CBD resection with HJ reconstruction is required; in some cases of Klatskin tumours a right hepatectomy can be added depending on the involvement or not of the right hepatic duct. When Mirizzi syndrome is type IIC, with an aborted stone inside the CBD and more than 50% of its diameter destroyed, the HJ is the best reconstruction option, Mirizzi syndrome type IIB can also be considered as an indication. Palliative biliary bypass in advanced pancreatic cancer is usually managed by ERCP and stenting. When it's not possible to place the stent through the ampulla of Vater and the attempt at PTC fails to insert an internal-external catheter, the HJ comes to be an indication.

Most of our cases involved patients with multiple CBD stones that couldn't be completely swapped after many trials of ERCP. In one case the patient underwent 9 trials of ERCP. To date, there is no consensus of the definition of multiple or pan choledochal-lithiasis, some authors use as cut line 5 or more stones (Houghton and collaborators)⁽⁹⁾ and

others 2 or more (Wo and collaborators)⁽¹⁰⁾. Our patients presented uncountable number of CBD stones, far away above the 5 stones of Wo and collaborators. Of those 12 cases, 5 had sickle anemia, a well-known risk factor for developing CBD stones.

A leak was found in one case of choledochal cyst Todani type IV. It was noticed that the CBD wall was not thick enough to hold the stitches properly. PDS 4-0 was used. Due to the leak, a bilioma was formed, and it was treated by percutaneous drainage. The patient with re-Hepaticojejunal-anastomosis due to stenosis developed a wound infection at the umbilical port side that was managed by antibiotics and bedside drainage. The rest of the group had a successful recovery with a return to work after 15 days, except for cancer patients, for which they were scheduled for chemotherapy. In the close follow-up no jaundice was noticed, and there was no cholangitis as well.

The blood loss is minimal in most of the laparoscopic approaches when compared to open surgery⁽¹¹⁾. Laparoscopic hepaticojejunostomy demands clear knowledge of the biliary system and well-trained surgeons in advanced laparoscopic procedures⁽¹²⁾.

We believe that the key to success in LH includes two items:

- 1) excellent knowledge of biliary anatomy and pathophysiology, the intra-op cholangiogram plays a significant role in the final understanding of the scenario.
- 2) pre-trained surgeons in advanced laparoscopic procedures in the hepato-biliary field.

shown benefits about postoperative recovery and low blood loss.

We didn't compare our cases with an open approach; our purpose is to expose what we did in terms of minimally invasive surgery.

Conclusion

Major surgical procedures have moved towards to minimally invasive approaches. Our first 21 consecutive LH cases without patient selection have



References

1. Stefanini P, Carboni M, Patrassi N, Basoli A, de Bernardinis G, Negro P. Roux-en-Y hepaticojejunostomy: a reappraisal of its indications and results. *Ann Surg.* 1975 Feb;181(2):213-9. doi: 10.1097/0000658-197502000-00016.
2. Mirizzi P, Quiroza L. La exploración de las vías biliares principales en el curso de la operación. *Proc Third Argent Cong Surg.* 1931; 1:694.
3. Mirizzi P. Physiologic sphincter of the hepatic bile duct. *Arch Surg* 1940; 41(6):1325-1333.
4. Praderi R, Gil J. Los cinco síndromes de la obstrucción biliar. *Cir Uruguay* 1998; 68: 75-79.
5. Goessmann H, Lang SA, Fichtner-Feigl S, Scherer MN, Schlitt HJ, Stroszczyński C, Schreyer AG, Schnitzbauer AA. Biliodigestive Anastomosen: Indikationen, Komplikationen und interdisziplinäres Management [Biliodigestive anastomosis: indications, complications and interdisciplinary management]. *Chirurg.* 2012 Dec;83(12):1097-108. German. doi: 10.1007/s00104-012-2365-z.
6. Antolovic D, Koch M, Galindo L, Wolff S, Music E, Kienle P, Schemmer P, Friess H, Schmidt J, Büchler MW, Weitz J. Hepaticojejunostomy--analysis of risk factors for postoperative bile leaks and surgical complications. *J Gastrointest Surg.* 2007 May;11(5):555-61. doi: 10.1007/s11605-007-0166-3.
7. Hepp J, Couinaud C. L'abord et l'utilisation du canal hépatique gauche dans les réparations de la voie biliaire principale [Approach to and use of the left hepatic duct in reparation of the common bile duct]. *Presse Med (1893).* 1956 May 23;64(41):947-8. French
8. Schreuder AM, Franken LC, van Dieren S, Besselink MG, Busch OR, van Gulik TM. Choledochoduodenostomy versus hepaticojejunostomy - a matched case-control analysis. *HPB (Oxford).* 2021 Apr;23(4):560-565. doi: 10.1016/j.hpb.2020.08.014.
9. Houghton, E. J., Buccini, F., Presta, A., Pedreira, D., Diz, G., Rubio, J. S. Panlitiiasis coledociana: ¿es la derivación biliodigestiva todavía una opción? *Acta Gastroenterol Latinoam* 2018;48(1):07-12.
10. Wu Y, Xu CJ, Xu SF. Advances in Risk Factors for Recurrence of Common Bile Duct Stones. *Int J Med Sci.* 2021 Jan 1;18(4):1067-1074. doi: 10.7150/ijms.52974.
11. Miyano G, Koyama M, Miyake H, Kaneshiro M, Morita K, Nakajima H, Yamoto M, Nouse H, Fukumoto K, Urushihara N. Comparison of laparoscopic hepaticojejunostomy and open hepaticojejunostomy. Can stenosis of the hilar hepatic duct affect postoperative outcome? *Asian J Endosc Surg.* 2017 Aug;10(3):295-300. doi: 10.1111/ases.12358.
12. Palermo M, Trelles N, Gagner M. Laparoscopic revisional hepaticojejunostomy for biliary stricture after open repair following common bile duct injury: a case report. *Surg Innov.* 2011 Mar;18(1):105-9. doi: 10.1177/1553350610395033.

**Conflicto de interés:**

Ninguno.

Limitaciones de responsabilidad

La responsabilidad de esta publicación es de los autores.

Fuentes de apoyo

La presente investigación no contó con fuentes de apoyo.

Originalidad

Este artículo es original y no ha sido enviado para su publicación a otro medio de difusión científica en forma completa ni parcialmente.

Cesión de derechos

Quienes participaron en la elaboración de este artículo, ceden los derechos de autor a la Universidad Nacional de Córdoba para publicar en la Revista de la Facultad de Ciencias Médicas de Córdoba y realizar las traducciones necesarias al idioma inglés.

Contribución de los autores

Quienes participaron en la elaboración de este artículo, han trabajado en la concepción del diseño, recolección de la información y elaboración del manuscrito, haciéndose públicamente responsables de su contenido y aprobando su versión final.

Agradecimientos

To the wonderful group of general surgery residents of KFGH in Jeddah.