

Amyand's hernia complicated with appendicitis

Hernia de Amyand complicada con apendicitis

Hérnia de Amyand complicada com apendicite

Franco Corvatta¹, Fanny Rodriguez Santos², Federico Mazzini³, Ignacio Fuente⁴

El hallazgo de un apéndice normal dentro de una hernia inguinal ocurre en alrededor del 1% de los casos. Sin embargo, la combinación de una apendicitis (inflamación del apéndice) y una hernia inguinal atascada es una entidad aún más rara, presentada en menos del 0,8% de los casos. En este trabajo presentamos un caso y discusión sobre la literatura disponible, exponiendo acerca de la presentación clínica, el diagnóstico y tratamiento de esta patología. Cabe destacar la utilidad de la Tomografía Computada como estudio complementario previo a realizar el tratamiento quirúrgico.

Key concept:

a. What do we know about the subject?

Amyand's hernia is a rare entity that requires an adequate preoperative diagnosis.

b. How does this article contribute to the subject?

This article provides a review of the available literature for the approach to Amyand hernia.

Abstract:

Introduction: The finding of a vermiform appendix within the peritoneal sac of an indirect inguinal hernia occurs in approximately 1% of cases. However, the presence of appendicitis within an inguinal hernial sac is found only in 0.08% of the general population.

Case report: We present the case of a 58-year-old male patient that was admitted with abdominal pain associated with a small non-reducible right groin mass.

Discussion: To establish the correct diagnosis preoperatively, an abdominal and pelvic CT scan is mandatory.

Conclusion: Acute appendicitis in an Amyand's hernia is a very rare entity that can be easily misdiagnosed preoperatively. CT is extremely useful in reaching the correct preoperative diagnosis.

Keywords: *Hernia; Appendicitis; Tomography, X-Ray Computed*

Resumen:

Introducción: El hallazgo de un apéndice vermiforme dentro del saco peritoneal de una hernia inguinal indirecta ocurre en aproximadamente el 1% de los casos. Sin embargo, la presencia de apendicitis dentro de un saco herniario inguinal se encuentra sólo en el 0.08% de la población general.

Caso clínico: Presentamos el caso de un paciente masculino de 58 años que ingresa por dolor abdominal asociado a una pequeña masa inguinal derecha no reducible.

Discusión: Para establecer el diagnóstico correcto preoperatorio, es obligatoria una tomografía computarizada de abdomen y pelvis.

Conclusión: La apendicitis aguda en la hernia de Amyand es una entidad muy rara que puede diagnosticarse erróneamente fácilmente en el preoperatorio. La TC es de gran utilidad para llegar al correcto diagnóstico preoperatorio.

Palabras clave: *Hernia; Apendicitis; Tomografía Computarizada por Rayos X*

Resumo

Introdução: O achado de apêndice vermiforme dentro do saco peritoneal de hérnia inguinal indireta ocorre em aproximadamente 1% dos casos. No entanto, a presença de apendicite dentro de um saco herniário inguinal é encontrada apenas em 0,08% da população geral.

Caso clínico: Apresentamos o caso de um paciente do sexo masculino, 58 anos, que deu entrada por dor abdominal associada a pequena massa inguinal à direita, não redutível.

Discussão: Para estabelecer o diagnóstico pré-operatório, a tomografia computadorizada de abdome e pelve é obrigatória.

Conclusão: A apendicite aguda na hérnia de Amyand é uma entidade muito rara que pode ser facilmente diagnosticada no pré-operatório. A TC é muito útil para se chegar ao diagnóstico pré-operatório correto.

Palavras-chave: *Hérnia; Apendicite; Tomografia Computadorizada por Raios X*

1- MD, Resident, Department of General Surgery of Hospital Italiano de Buenos Aires, Argentina. Contact Mail: franco.corvatta@hospitalitaliano.org.ar

2- MD, Contracted surgeon, Specialist in Phlebology, Department of General Surgery of Hospital Italiano de Buenos Aires, Argentina

3- MD, Contracted surgeon, Specialist in Trauma Surgery, Department of General Surgery of Hospital Italiano de Buenos Aires, Argentina

4- MD, Contracted surgeon, Specialist in Oesophagogastric and Duodenal Surgery, Department of General Surgery of Hospital Italiano de Buenos Aires, Argentina.

Recibido: 2020-10-28 Aceptado: 2021-09-22

DOI: <http://dx.doi.org/10.31053/1853.0605.v78.n3.30705>



© Universidad Nacional de Córdoba

INTRODUCTION

The finding of a vermiform appendix within the peritoneal sac of an indirect inguinal hernia was first described by De Garegeot in 1731 (1). This incidental finding occurs in approximately 1% of cases of inguinal hernia (2), however, the presence of appendicitis within an inguinal hernial sac is found only in 0.08% of the general population (3). In 1735 Claudius Amyand performed the first appendectomy through an inguinal herniotomy, giving the name to this entity (1).

CASE REPORT

A 58-year-old male patient with unremarkable past medical history was admitted to the emergency department for abdominal pain. Physical examination revealed a distended abdomen without peritoneal signs. A small non-reducible right groin mass with severe tenderness to palpation was noted. After clinical evaluation, a laboratory was performed showing a white blood cell count of 16.500/mm³ (normal range: 4.000- 11.000/mm³). A Computed tomography (CT) showed right inguinal hernia with an incarcerated, inflamed vermiform appendix with an air-fluid level (**Figure 1**).

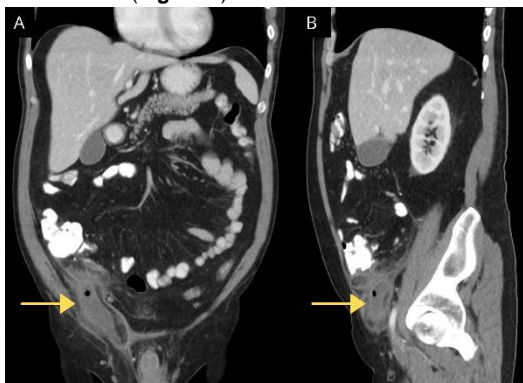


Figure 1: Abdominal computed tomography showing right inguinal hernia with an incarcerated, inflamed vermiform appendix (yellow arrow).

Based on the presumptive diagnosis of acute appendicitis, we carried out a laparoscopic approach. During exploration, we found the appendix protruding through the right deep inguinal ring (**Figure 2 A-B**). As a remarkable note, we found a left inguinal hernia with no signs of complications. The herniated appendix was reduced into the abdominal cavity, evidencing an 8 x 6 cm appendix (**Figure 2 C-D**).

A standard laparoscopic appendectomy was performed. The postoperative course was uneventful and the patient was discharged the following day. The pathology report was consistent with acute phlegmonous appendicitis.

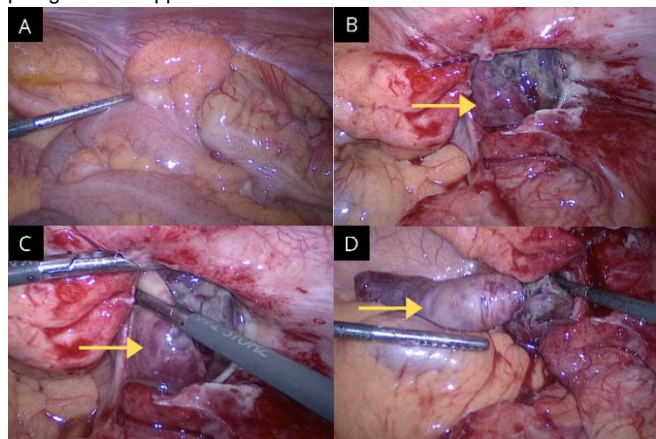


Figure 2: A-B: Appendix protruding through the right deep inguinal ring (yellow arrow). C-D: Appendix reduced into the abdominal cavity (yellow arrow).

DISCUSSION

The finding of an inflamed appendix within an inguinal hernial sac occurs in less than 0.1% of cases of the general population (3). This entity has been reported in a variety of ages, from 3 weeks to 88 years old. Males are more often affected by inguinal hernias. However, the concomitant occurrence of acute appendicitis in the sac of a crural hernia is more frequent in females (4). The clinical presentation does not differ from an acute appendicitis, with abdominal pain and tenderness in the lower right quadrant, associated with a non-reducible groin mass due to an inguinal or femoral hernia. Differential diagnosis has to be made with epiploic strangulation and Richter's hernia (4). The diagnosis is rarely established preoperatively in patients without a palpable groin mass. Imaging studies such as abdominal and pelvic CT can demonstrate a blind-ending tubular structure arising from the caecum which extends into the inguinal sac. A dilated lumen, enhanced and thickened wall, and striation of adjacent peri-appendiceal fat are suggestive signs of acute appendicitis. Ultrasonography (USG) can also demonstrate the extension of the appendix into the inguinal sac, and in case of acute inflammation, the appendix is dilated, non-compressible, thickened and hypervascular. Therefore, USG is an useful radiation-free imaging modality for children and pregnant women (5). Although abdominal CT may be helpful in reaching the correct diagnosis, in the vast majority of the cases the diagnosis is confirmed intraoperatively (6). Regarding the treatment of complicated Amyand's hernias, Losanoff et al established a classification in order to improve their management. In the presence of an Amyand's hernia complicated with acute appendicitis, reduction of the hernia with mesh-free repair of the inguinal floor associated with appendectomy is recommended (7). However, an individualized approach must be performed since it depends on the state and integrity of the appendix.

Published evidence regarding appendicitis in an Amyand hernia describes a combined treatment of appendectomy plus hernia repair (4,7). In the present case, inguinal repair was not performed due to small size of the right defect in addition to the finding of bilateral inguinal hernia. Considering that the patient will undergo a second surgery for left inguinal hernia and taking into account that the surgery was carried out during the COVID-19 outbreak and a reduced surgery time was sought, we decided to only reduce the content of the inguinal hernia and perform the laparoscopic appendectomy.

CONCLUSION

Acute appendicitis in an Amyand's hernia is a very rare entity that can be easily misdiagnosed preoperatively. CT is extremely useful in reaching the correct preoperative diagnosis.

Limitations of Liability

The information contained in this article is only the responsibility of the authors.

Conflict of Interest: No conflict of interest to disclose.

Source of Funding: None

Originality of the work

This article is original and has not been submitted for publication in whole or in part to any other scientific journal.

Assignment of rights

The participants in this work cede copyright to the Universidad Nacional de Córdoba for publication in the Revista de la Facultad de Ciencias Médicas and for any translations that may be necessary.

Informed consent statement: Informed patient consent was obtained for case publication.

Reference

1. Thomas WE, Vowles KD, Williamson RC. Appendicitis in external herniae. *Ann R Coll Surg Engl*. 1982 Mar;64(2):121-2.
2. Singh K, Singh RR, Kaur S. Amyand's hernia. *J Indian Assoc Pediatr Surg*. 2011 Oct;16(4):171-2. doi: 10.4103/0971-9261.86890.
3. García-Cano E, Martínez-Gasperin J, Rosales-Pelaez C, Hernández-Zamora V, Montiel-Jarquín JÁ, Franco-Cravioto F. Hernia de Amyand y apendicitis complicada; presentación de un caso y elección de tratamiento quirúrgico [Amyand's hernia and complicated appendicitis; case presentation and surgical treatment choice]. *Cir Cir*. 2016 Jan-Feb;84(1):54-7. Spanish. doi: 10.1016/j.circir.2015.06.012
4. D'Alia C, Lo Schiavo MG, Tonante A, Taranto F, Gagliano E, Bonanno L, Di Giuseppe G, Pagano D, Sturniolo G. Amyand's hernia: case report and review of the literature. *Hernia*. 2003 Jun;7(2):89-91. doi: 10.1007/s10029-002-0098-5.
5. Tsang WK, Lee KL, Tam KF, Lee SF. Acute appendicitis complicating Amyand's hernia: imaging features and literature review. *Hong Kong Med J*. 2014 Jun;20(3):255-7. doi: 10.12809/hkmj133971.
6. Yagnik VD. Amyand hernia with appendicitis. *Clin Pract*. 2011 Apr 22;1(2):e24. doi: 10.4081/cp.2011.e24.
7. Losanoff JE, Basson MD. Amyand hernia: a classification to improve management. *Hernia*. 2008 Jun;12(3):325-6. doi: 10.1007/s10029-008-0331-y.