

Case Report**A RARE CASE OF TENDINOUS INSERTION OF CORACOBRACHIALIS ASSOCIATED WITH VARIANT MUSCULOCUTANEOUS NERVE****Khizer H. A. Mookane, Sangeeta Muralidharan***Department of Anatomy, MVJ Medical College and Research Hospital, Bangalore, Karnataka, India***ABSTRACT**

We report a rare case of the tendinous insertion of coracobrachialis muscle which has not been reported in the literature. The insertion of the novel coracobrachialis muscle is usually into the medial border of the humerus in a 3-5cm impression at the mid-shaft level. Contrary to this, in the present case, it was seen getting inserted as a sharp slender tendon in the middle of the medial border of the humerus. Variable insertion of coracobrachialis muscle may be responsible for the causation of compression of surrounding structures like median nerve, musculocutaneous nerve, and brachial artery. This article aims to point out a rare case of the unusual tendinous insertion of coracobrachialis and its association with musculocutaneous nerve, providing necessary information to surgeons performing surgical reconstruction using coracobrachialis.

Keywords: *Coracobrachialis muscle; musculocutaneous nerve; median nerve.*

RESUMEN

Presentamos un caso raro de inserción tendinosa del músculo coracobraquial que no se ha informado en la literatura. La inserción del nuevo músculo coracobraquial generalmente se realiza en el borde medial del húmero en una impresión de 3-5 cm a nivel del eje medio. Contrariamente a esto, en el presente caso, se observó que se insertaba como un tendón delgado y afilado en el medio del borde medial del húmero. La inserción variable del músculo coracobraquial puede ser responsable de la causa de la compresión de las estructuras circundantes, como el nervio mediano, el nervio musculocutáneo y la arteria braquial. Este artículo tiene como objetivo señalar un caso raro de la inserción tendinosa inusual del coracobraquial y su asociación con el nervio musculocutáneo, brindando la

información necesaria a los cirujanos que realizan la reconstrucción quirúrgica usando el coracobraquial.

Palabras clave: *músculo coracobraquial; nervio musculocutáneo; nervio mediano.*

INTRODUCTION

Coracobrachialis muscle (CB) is chiefly a flexor muscle, although in the arm it corresponds to the adductor mass seen in the thigh which has become insubstantial in human beings during the process of evolution. It develops from a tissue mass forming the biceps and brachialis and is supplied by musculocutaneous nerve (MCN) (Bergman, 1988). Usually a novel CB originates from the tip of the coracoid process of the scapula in common with the short head of the biceps brachii muscle. The insertion of the muscle is usually into medial border of the humerus in a 3-5cm impression at mid-shaft level between the attachments of triceps and brachialis. CB forms an inconspicuous rounded ridge on the upper medial side of the arm (Williams et al., 1995).

Generally as a rule, CB is pierced and innervated by MCN. But however, few authors in the literature have reported that MCN does not pierce the CB. Variations in the insertion of CB have been reported by various authors in the literature.

* *Correspondence to:* **Khizer H. A. Mookane.**
drafroze.homoeo@gmail.com

Received: 20 May, 2020. **Revised:** 13 June, 2020.
Accepted: 19 June, 2020.

These variations include as accessory slip of the CB inserting 1) to medial epicondyle 2) to medial supracondylar ridge of the humerus 3) to medial intermuscular septum of the arm and 4) to lesser tubercle (Illyperuma et al., 2016; Bohnel, 1979; El-Naggar, 2001; Guha et al., 2010; Kopuz et al., 2002). This article aims to point out a rare case of

unusual tendinous insertion of CB and its association with MCN, providing necessary information to surgeons performing reconstruction, both post mastectomy and infraclavicular defects, muscle transfer in cases of facial paralysis, and procedures mandating axillary block.

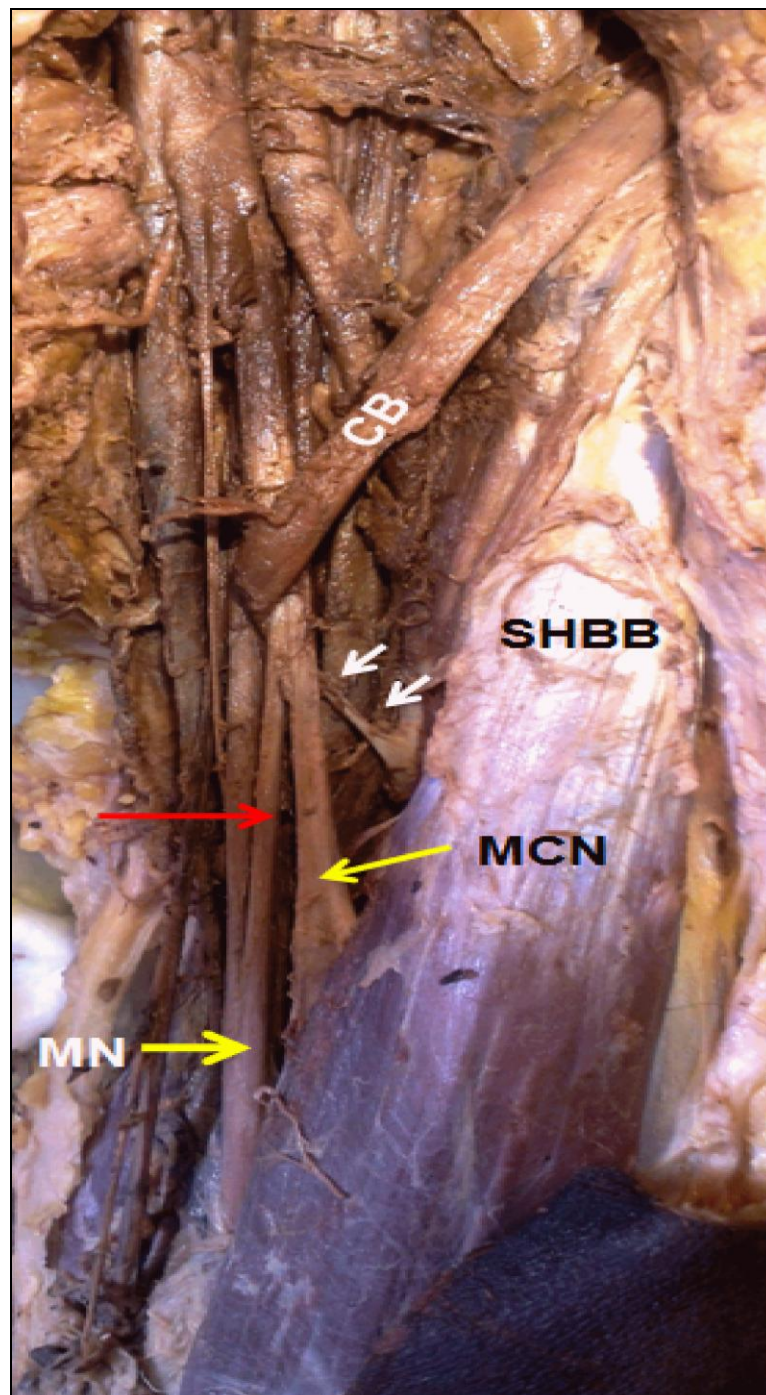


Figure 1- White arrow indicates the slender insertion of Coracobrachialis (CBM), yellow arrow indicates Musculocutaneous Nerve (MCN) and Median Nerve (MN). Red arrow indicates communicating branch between Musculocutaneous Nerve and Median Nerve

CASE REPORT

During the regular dissection of 62 years old formalin embalmed male cadavers of south Indian origin in the Department of Anatomy at MVJ Medical College and Research Hospital, we came across a rare anatomical variation in the flexor compartment of the left arm. When anterior compartment muscles of arm were dissected from its origin to the insertion following the steps in Cunningham's dissection manual, we observed a variation in the insertion of CB.

Usually the CB ends on an impression, 3–5 cm in length and is inserted into the middle of the medial border of the humerus, but in the present case, CB was observed getting inserted as sharp slender tendon in the middle of the medial border of the humerus. In addition to this variation, we also observed the musculocutaneous nerve passing underneath this slender tendon. The MCN was seen to be arising normally from the lateral cord of brachial plexus running downwards and laterally to pass beneath the slender tendon of CB. The formation of median nerve (MN) was seen to be normal. Communicating branch between the MN and MCN was encountered after latter passed underneath this slender tendon (Figure 1).

DISCUSSION

An anomaly in the CB is not uncommon but such anomalies have not been well documented. Anomalies are encountered more in distal attachment (insertion) than proximal attachment (origin) of CB. Variations in the insertion of CB have been reported by various authors in the literature. These variations include as accessory slip of the CB inserting 1) to medial epicondyle 2) to medial supracondylar ridges of the humerus 3) to medial intermuscular septum of the arm and 4) to lesser tubercle (Ilayeruma et al., 2016).

Kopuz C et al. (2002) stated that Wood (1867) was the first to propose three parts of CB: the upper part inserted to the capsule of the shoulder joint (CB superior or brevis or rotator humeri); the middle part to the mid-part of the humerus (CB proprius or medius); the lower part to the internal condyloid ridge, the internal intermuscular septum, or the trochlea (CB longus).

We can enlighten these variations by means of comparative anatomy. Study conducted in amphibians, reptiles, and monotremes showed that the coracobrachialis muscle has three heads each of which inserted into 1) the humerus superior to tendon of latissimus dorsi – coracobrachialis brevis (profundus), 2) the

humerus inferior to tendon of latissimus dorsi - coracobrachialis medius (proprius), 3) inferiorly on the shaft of humerus bridging the median nerve and brachial artery - coracobrachialis longus (superficialis) (Howell and Straus, 1932; Sonntag, 1923).

Similar classification was put forth by Kyou-Jouffroy et al. (as cited by Georgiev et al., 2018). In contrast, Mori (1964) conducted the study on Japanese population and concluded that the CBM was divided into superficial and deep layers.

The intrinsic muscles of the upper limb develop from the limb bud mesenchyme of lateral plate mesoderm. The muscle mass may eventually differentiate into different layers of muscles which may fuse to form a single muscle mass followed by apoptosis of some muscle mass (El-Naggar, 2001). This has resulted in fusion of coracobrachialis medius and longus which gets inserted in a diffuse manner to the medial border of humerus at mid shaft level. Persistence of coracobrachialis brevis may present as accessory slip of CB in humans which gets inserted to lesser tubercle or capsule of shoulder joint. From the above explanation, it is evident that slender CB observed in our case was remnant of coracobrachialis medius, longus being absent.

Our second observation was MCN passing underneath the slender tendon of CB. Wide variation in MCN (0-22%) have been reported in the previous literature. Loukas and Aqueelah (2005) conducted a study on 258 arms and postulated the 4 types of communication of MCN with MN in relation to CB. He categorized these communications into following types. Type I - communication with MN proximal to entry of the MCN into CB. Type II - communication with MN distal to entry of the MCN into CB. Type III – MCN does not pierce CB. Type IV- combination of I and II. Variation of MCN observed in the present case report falls under type II.

Change in the course of MCN as observed in our case can be accounted for the change in the muscle bulk of coracobrachialis (CB longus being absent). In cases where the part of CB normally pierced by MCN is missing, MCN does not pierce CB as was observed in our case (Ilayeruma et al., 2016).

In conclusion, an anatomical variation of CB has become significant with the widespread use of Computed Tomogram (CT) and Magnetic Resonance Imaging (MRI) wherein any variation in CB can be misinterpreted for any other muscle. Knowledge of these kinds of variations are important as CB has also been used as a graft for chronic acromioclavicular dislocations, breast reconstructive surgeries Long standing facial

paralysis has also been treated effectively with CB flap . The MCN can get trapped underneath CB as in our case, causing paresthesia in the cutaneous area of distribution of the nerve associated with poor flexion of the elbow.

Conflict of interest

Nil

Funding

Nil

Informed consent

Not Applicable

Ethical approval

It was obtained from the ethical committee of the institution

Contributions

The authors in this article have made the following contribution - MKHA: Study design, dissection of specimen, manuscript editing, figure editing; SM: manuscript editing, literature research.

REFERENCES

Bergman R. 1988. Compendium of human anatomic variation: text, atlas, and world literature, Baltimore, Urban & Schwarzenberg.
Böhnel P. 1979. Variant of the coracobrachialis muscle (accessory origin from the shoulder joint capsule). *Handchirurgie* 1: 119-20.
El-Naggar MM. 2001. A study on the morphology of the coracobrachialis muscle and its

relationship with the musculocutaneous nerve. *Folia morphologica* 60: 217-24.

Georgiev GP, Tubbs RS, Landzhov B. 2018. Coracobrachialis Longus Muscle. *Humero-epitrochlearis*. *Cureus* 10: 1-5.

Guha, R, Satyanarayana, N, Reddy CK, Jayasri, N, Nitin, V, Praveen G, Datta, AK. 2010. Variant insertion of coracobrachialis muscle – morphological significance, embryological basis and clinical importance. *Journal of College of medical sciences-Nepal* 6: 42-46.

Howell AB, Straus WL. 1931. The brachial flexor muscles in primates. *Proceedings of the United States National Museum*.

Ilayperuma I, Nanayakkara BG, Hasan R, Uluwitiya SM, Palahepitiya KN. 2016. Coracobrachialis muscle: morphology, morphometry and gender differences. *Surgical and Radiologic Anatomy* 38:335-40.

Kopuz C, Icten N, Yildirim M. 2002. A rare accessory coracobrachialis muscle: a review of the literature. *Surgical and Radiologic Anatomy* 24: 405-09.

Loukas M, Aqueelah H. 2005. Musculocutaneous and median nerve connections within, proximal and distal to the coracobrachialis muscle. *Folia morphologica*, 64: 101-08.

Mori M. 1964. Statistics on the musculature of the Japanese. *Okajimas folia anatomica japonica* 40: 195-300.

Sonntag CF. 1923. On the anatomy, physiology, and pathology of the chimpanzee. In *Proceedings of the Zoological Society of London* 93: 323-429.

Williams PL, Bannister LH, Berry MM, Collins P, Dyson M, Dussek JE. 1995. Muscle. In *Gray's Anatomy* 38th Ed. Edinburgh: Churchill Livingstone; p 842.