

Case Report**THE COEXISTENCE OF ILIACUS MUSCLE VARIATION AND FEMORAL NERVE SPLIT: A CASE REPORT AND POSSIBLE CLINICAL IMPLICATIONS****Sameer R. Dhumale¹, Abdulmenem Alashkham^{1,2}**¹*Centre for Human Anatomy, School of Biomedical Sciences, University of Edinburgh, Edinburgh, United Kingdom*²*Human Anatomy Department, Faculty of Medicine, University of Zawia, Zawia, Libya***RESUMEN**

La variación del músculo íliaco coexistiendo con la división del nervio femoral fueron descubiertos durante la disección anatómica rutinaria de la Fosa íliaca en un cadáver fijado. La disección cuidadosa reveló una ramificación anormal del nervio femoral alrededor de una división accesoria del musculo iliaco, llamado iliacus minimus. Pensamos que la coexistencia de una ramificación del nervio femoral con divisiones musculares aberrantes aumenta la posibilidad de compresión del nervio. Los resultados publicados aquí apoyan muchos otros casos de ramificación del nervio femoral inusuales y destacan la relevancia en las pruebas diagnósticas, los métodos por imágenes y el tratamiento de la patología dentro de la fosa iliaca. Comprender y reconocer las variaciones anatómicas son fundamentales para médicos especialistas y docentes, particularmente anatomistas, radiólogos y cirujanos con el fin de mejorar la práctica médica.

Palabras clave: Anatomía, nervio femoral, variación, ramificación, fosa iliaca

ABSTRACT

The iliacus muscle variation and coexisting femoral nerve split were discovered during routine anatomical dissection of iliac fossae in an embalmed cadaver. Careful dissection revealed abnormal branching of the femoral nerve around a muscular slip of iliacus, named iliacus minimus. We reason that the coexistence of a femoral nerve split with aberrant muscular slips increases the chance of nerve compression. The findings reported here support many other cases of unusual femoral nerve branching and highlight the impact on diagnostic testing, imaging and treatment of pathology within the iliac compartment. Understanding and recognising anatomical variation is critical for medical specialists and educators, particularly anatomists, radiologists and surgeons in order to improve medical practice.

Key words: Anatomy; femoral nerve; variation; branching; iliac compartment.

INTRODUCTION*Iliacus*

Iliacus is a broad muscle lining the iliac compartment of the posterior abdominal wall and is considered the main flexor of the hip joint. It arises from the superior aspect of the inner edge of the iliac crest, anterior sacro-iliac and ilio-lumbar ligaments, the superior aspect of the lateral surface of the sacrum and capsule of the hip joint. The iliacus converges with psoas major on its inferomedial aspect, before combining to form iliopsoas. It attaches to the lesser trochanter of the femur and to the femur just inferior to the lesser trochanter (Sinnatamby, 2011), and is supplied by a division of the femoral nerve (Drake et al, 2013; Moore et al, 2015).

Accessory slips of iliacus have been documented as these may influence current surgical procedures and methods of intervention (Spratt et al, 1996; Jeleu et al, 2005). Variable muscle masses will inevitably change the course and structure of surrounding anatomy such as vessels and nerves, causing further implications for surgery in this region.

* Correspondence to: **Sameer Raj Dhumale..**
Sameer.Dhumale@ed.ac.uk

Received: 3 June, 2016. **Revised:** 21 June, 2016. **Accepted:** 6 July, 2016.

Reported variations of iliacus show either an accessory or aberrant slip of iliacus, or iliacus minimus (a defined muscle with its own origin and insertion), or both. Examples have been documented in the past whereby both have coexisted within a femoral nerve split, such as presented by Rao et al (2008).

In this instance, unusual muscle separation of iliacus was encountered, as well as unusual unilateral splitting of the femoral nerve within the iliac fossa, encircling an identified aberrant slip of iliacus.

The femoral nerve

The femoral nerve is an essential conduit of motor and sensory innervation to the lower limb. It stems from the posterior divisions of ventral rami of the second, third and fourth lumbar nerves (L2-L4), as part of the lumbar plexus. The nerve courses through psoas major, emerging from its inferolateral margin within the iliac fossa of the posterior abdominal wall. Then, it courses obliquely across the iliac fossa superior to iliacus and within the iliac fascia, before continuing under the inguinal ligament lateral to the femoral artery. At the level of the inguinal ligament, it

divides into: (1) cutaneous branches which includes intermediate cutaneous nerve of thigh, medial cutaneous nerve of thigh and, saphenous nerve; (2) muscular branches which includes, nerve to Sartorius, nerve to pectineus, nerve to vastus medialis, nerve to vastus lateralis, nerve to vastus intermedius and nerve to rectus femoris; and (3) genicular branches to the hip and knee joints (Drake et al, 2013; Abrahams et al, 2013; Moore et al, 2015; Snell, 2012; Sinnatamby, 2011). Injury of the femoral nerve leads to motor and sensory deficits. The motor effects are paralysis of the quadriceps which leads to loss of ability to extend the knee joint. Paralysis of Sartorius, pectineus and iliacus are not apparent clinically because of compensation by psoas major and adductor muscles (magnus, longus and brevis). The sensory effects include loss of sensation on the anteromedial thigh and the medial side of the leg and foot (Hansen, 2014). The femoral nerve is the largest branch of the lumbar plexus and therefore variation in its course and structure may have consequences manifesting in an array of clinical symptoms.

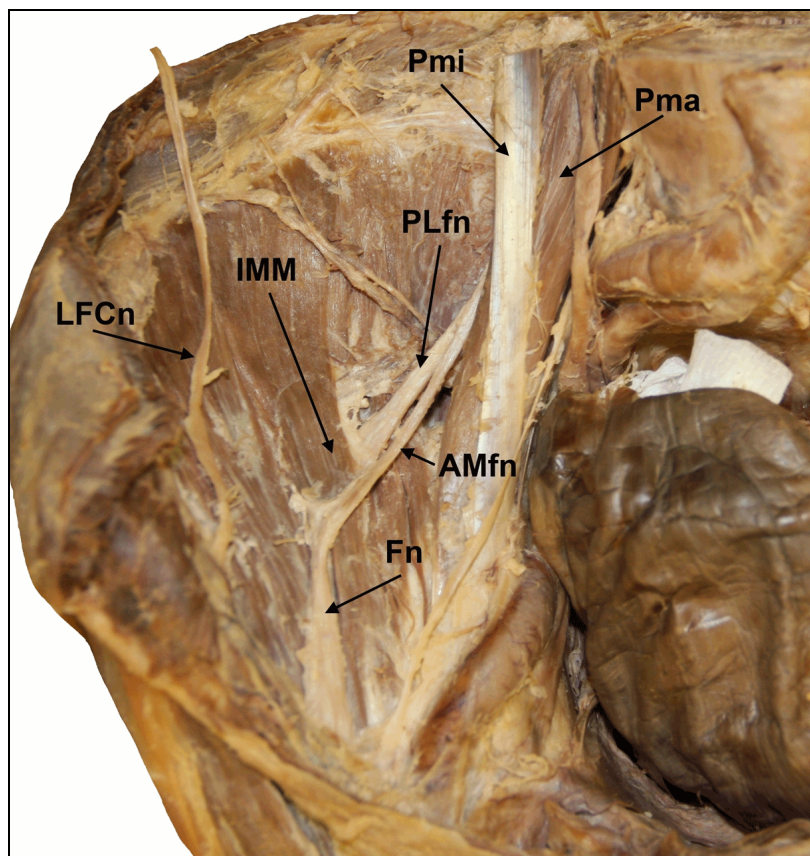


Figure 1. Anterior view of right iliac fossa shows the split femoral nerve; the anteromedial branch (AMfn) lies medial to iliacus minimus (IMM) and the posterolateral branch (PLfn) lies laterally.

CASE REPORT

The coexistence of a femoral nerve split and iliacus muscle variation were discovered during anatomical dissection of a previously dissected medical undergraduate teaching specimen. The specimen is from an embalmed (formaldehyde-fixed) 96 year old female without any visible medical disorders or known history of disease. Further dissection of the posterior abdominal wall uncovered the psoas major and minor muscles and respective tendons, followed by discovery of the trunk of the right femoral nerve where it emerged from the lateral aspect of the psoas major (fig. 1) as expected. Instant splitting of the nerve was evident as more iliac fascia was removed. The split of the femoral nerve encircled

an additional slip of iliacus (fig. 2), previously named iliacus minimus. The iliacus minimus divided the femoral nerve into an anteromedial branch and a larger posterolateral branch (fig. 3). The posterolateral branch emerged posterior to iliacus minimus and fused with the anteromedial branch at its lateral border. Then it was observed to continue on an oblique course through the iliac fossa before passing underneath the inguinal ligament and dividing into its anterior and posterior divisions consisting of the medial cutaneous nerve of the thigh, intermediate cutaneous nerve of the thigh, saphenous nerve, nerve to Sartorius, nerve to pectineus, nerve to vastus medialis, nerve to vastus lateralis, nerve to vastus intermedius and nerve to rectus femoris.

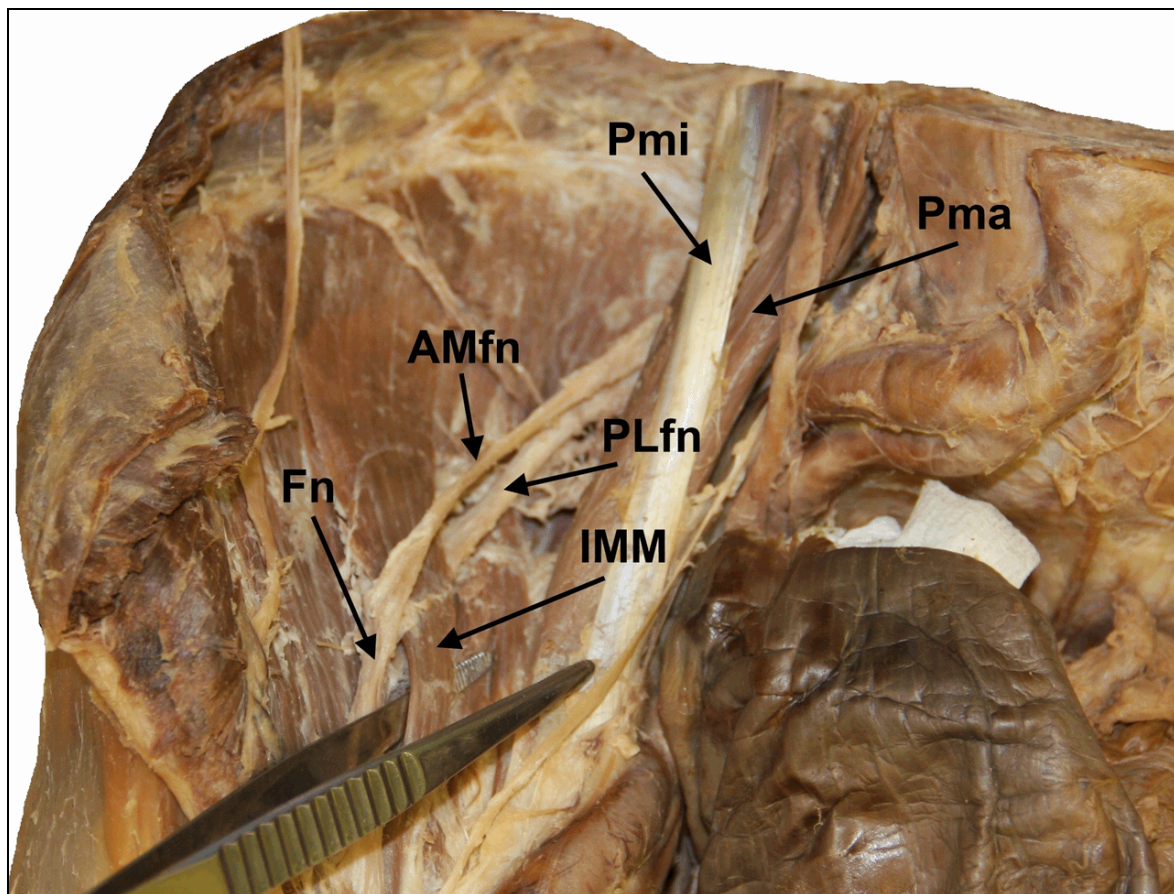


Figure 2. Anterior view of right iliac fossa shows IMM as a distinct muscle, separate from IM at its distal end just proximal to the inguinal ligament. The proximal end blended with IM. Both branches of the femoral nerve (AMfn and PLfn) clearly re-join on the lateral margin of IMM, to form the femoral nerve.

DISCUSSION

Reporting anatomical variation is crucial for the preservation of quality and efficient medical

practice, particularly in the surgical field. Variations of the femoral nerve can have consequences on the normal functioning of anatomical structures such as the femoral nerve

itself and surrounding anatomy. Entrapment within the iliac fossa is common (Astik and Dave, 2011; Anloague and Huibregts, 2009); therefore, a clear understanding of anatomic topography in this region is essential. In dissection of 34 cadaveric specimens, Anloague and Huibregts (2009) found a 35.3% (n=12) variation rate of the femoral nerve branching during lumbar plexus investigations. The femoral nerve was observed branching into medial and lateral divisions within the tissue of psoas major. This finding is similar to the results presented by Spratt et al (1996), with 4 out of 68 dissected specimens showing additional slips of iliacus and psoas major muscles splitting the femoral nerve. No involvement of psoas major tissue within a femoral nerve split was observed in this study. These muscular slips may be found during retroperitoneal surgery or through imaging of the iliopsoas compartment and should not be misdiagnosed (Lenchik et al, 1994). Additionally, disparities in the progression of the femoral nerve through the iliac fossa have implications for nerve block administration (Astik and Dave, 2011). Due

to the intervening muscular slip and early division of the femoral trunk, it is clear that an attempted femoral nerve block may be incomplete in such cases. As such, a more proximal level of administration of anaesthetic may be required, or an alternative method may be used such as an epidural blockade.

There have been many types of iliacus variation documented, usually coinciding with variation of the psoas major as they develop as the same muscular complex – iliopsoas. Surprisingly, our specimen only presented variation with the iliacus and not the psoas major. Accessory muscles are defined as having their own distinct origin and insertion, as well as nervous and blood supply. As defined by Aleksandrova et al (2013), our specimen possessed a single large aberrant slip. Involvement of the femoral nerve is rare and only Aleksandrova et al (2013) reported a similar finding. Within a 64 year old female cadaver, a small muscular slip of iliacus was identified along with a coexisting split femoral nerve. The femoral nerve was split into two short fibres before they reunited to reform the femoral nerve trunk.

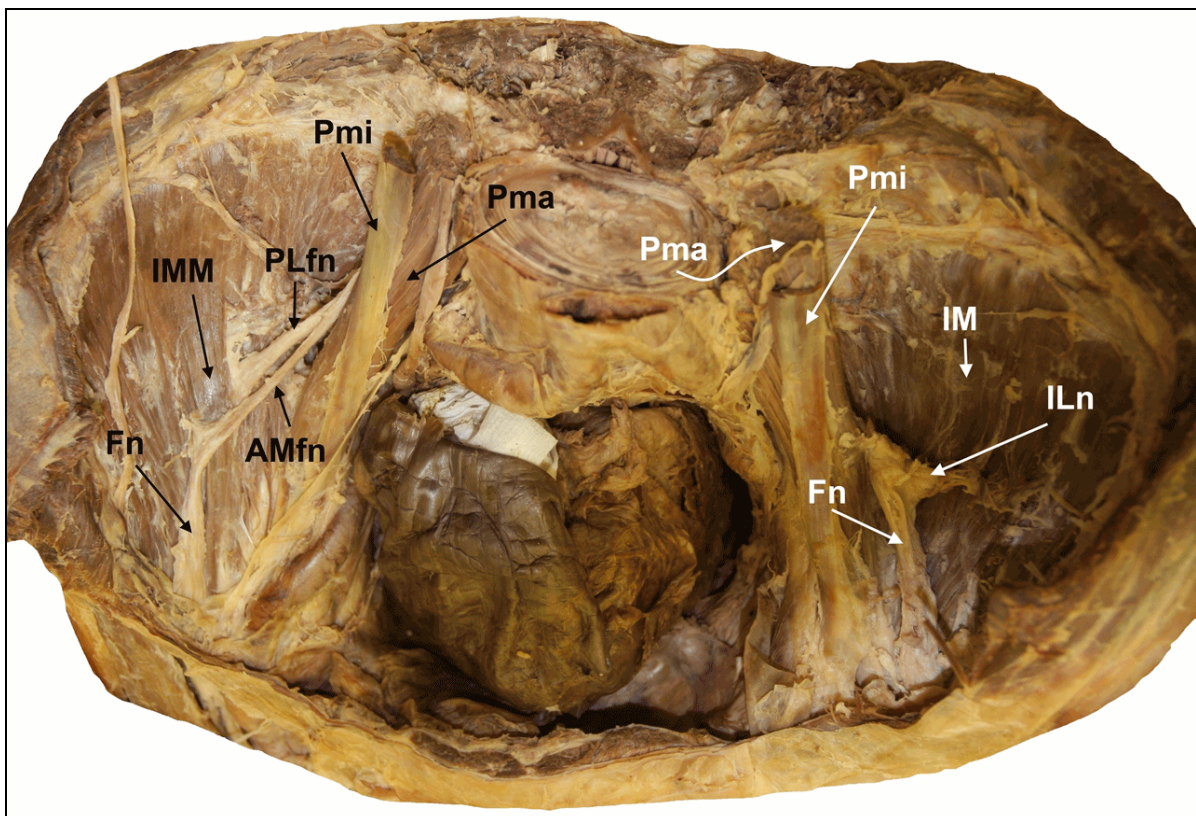


Figure 3. A superior view of both iliac fossae; the right iliac fossa (black arrows), shows the femoral nerve splitting and coursing around an accessory slip of iliacus. (IM- Iliacus; ILn- Nerve to iliacus; IMM- Iliacus minimus; Pma- Psoas major; Pmi- Psoas minor; Fn- Femoral nerve; PLfn- Posterolateral branch of femoral nerve; AMfn- Anteromedial branch of femoral nerve; LFCn- Lateral femoral cutaneous nerve). The left iliac fossa (white arrows), show normal distribution pattern of the femoral nerve with no IMM present.

Variations of the iliopsoas complex and subsequent nerve and slip formation may be explained by embryonic disruptions. The growing muscular blastema may have been penetrated by the aggressive ingrowths of the developing femoral nerve (Saadeh and Bergman, 1985).

Femoral nerve entrapment is rarely caused by muscular compression (Rao et al, 2008), however aberrant slips 'splitting' the femoral nerve present as a potential risk of nerve restriction. In the current study, as the PLfn passes underneath the IMM, there is a potential risk of nerve compression. Any pathology of IM or IMM may disrupt the function of the femoral nerve and subsequently may result in wasting of the quadriceps and paraesthesia in the anterior and middle compartments of the thigh (Aristotle et al, 2013). Few studies (Galzio et al, 1983; Jeleu et al, 2005) have reported IM hematoma and IMM abscess: assuming that could make the PLfn more vulnerable to entrapment.

Spratt et al (1996) coined the name 'iliacus minimus' and found that its unusual location in between femoral nerve branches may be the cause of referred hip and knee pain, as well as pain in the L2-L4 dermatome region. Additionally, they proposed IMM to be a potential cause of pain at the hip joint during hyperextension and lateral rotation. The branching pattern of Fn in the current study suggests this could occur due to its unusual position, however the range of movement observed with the AMfn suggests it is a fairly mobile structure and therefore is at less risk of tension during flexion, extension and rotation of the hip. A patient with a shorter AMfn may procure more movement difficulties; Anloague and Huijbregts (2009) proposed that limited mobility of the femoral nerve may lead to 'protective muscular guarding' due to increased 'neural mechano-sensitivity' in order to protect over stretching of the nervous tissue. This would disrupt the patient's locomotive ability.

An understanding of anatomical variation can improve diagnostic abilities. Battaglia et al (2012) highlighted that variations in the femoral nerve may devalue results obtained from investigations into lumbar nerve root impingement by nerve traction tests. As such, consideration of these variations can allow for earlier and more targeted testing for suspected lumbar disc herniation or deciphering between entrapment neuropathies and radiculopathy.

Variation in femoral nerve branching has been previously documented, suggesting its incidence is of great significance. The involvement of a variety of posterior abdominal wall muscles, namely psoas major, iliacus and an accessory slip of iliacus named iliacus minimus, is widely noted. The posterior branch of the split femoral

nerve, named here the posterolateral branch (PLfn), brings cause for concern considering its deep course. We conclude that medical specialists should be aware of this variation, as it may prove useful during imaging and treatment of the posterior abdominal wall and iliac compartment, and reduce the chances of iatrogenic femoral nerve palsy. The PLfn is also at greater risk of entrapment from pathology of surrounding tissue, particularly when considering the regular movement of structures within this anatomical space.

Conflict of Interest

None.

Funding

None.

Ethical approval

The cadaveric tissue was acquired and utilised in line with the Human Tissue Act (2004) and Anatomy (Scotland) Act 2006.

Informed Consent

Informed consent was obtained by the deceased prior to body donation.

Contribution

Dissection, data collection, imaging, analysis and writing up: SD. Analysis, imaging, editing and proof reading: AA

REFERENCES

- Abrahams PH, Spratt JD, Loukas M, Van Schoor AN. 2013. McMinn and Abraham's Clinical Atlas of Human Anatomy. 7th ed. London: Elsevier. Pp 321-22
- Alexandrova JN, Malinova Lina, Jeleu L. 2013. Variations of the Iliacus Muscle: Report of Two Cases and Review of the Literature. *International Journal of Anatomical Variations* 6: 149-52
- Anloague PA, Huijbregts P. 2009. Anatomical Variations of the Lumbar Plexus: A Descriptive Anatomy Study with Proposed Clinical Implications. *Journal of Manual and Manipulative Therapy* 17: 4
- Aristotle S, Sundarapandian S, Felicia C. 2013. Accessory Iliacus Muscle with Splitting of the Femoral Nerve: A Case Report. *OA Case Reports*. 6: 56
- Astik RB, Dave UH. 2011. Anatomical Variations in Formation and Branching Pattern of the

- Femoral Nerve in Iliac Fossa. *People's Journ of Sci Res.* 4: 2
- Battaglia PJ, Scali F, Enix DE.* 2012. Co-Presentation of Unilateral Femoral and Bilateral Sciatic Nerve Variants in One Cadaver: A Case Report with Clinical Implications. *Chiropractic and Manual Therapies.* 20: 34
- Drake RL, Vogl AW, Mitchell AWM.* 2015. *Gray's: Anatomy for Students.* 3rd ed. Philadelphia: Elsevier. Pp 368-401
- Galzio R, Luanotni D, Zenobii M, Cristuib-Grizzi L, Gadaleta A, Caffagni E.* 1983. Femoral Neuropathy Caused by Iliacus Hematoma. *Surg Neurology* 20: 254-57
- Hansen JT.* 2014. *Netter's Clinical Anatomy.* 3rd ed. Philadelphia: Elsevier. Pp. 334
- Jelev L, Shivarov V, Surchev L.* 2005. Bilateral Variations of the Psoas Major and the Iliacus Muscles and Presence of an Undescribed Variant Muscle – Accessory Iliopsoas Muscle. *Annals of Anat -Anatomischer Anzeiger* 3: 281-86
- Lenchik L, Dovgan DJ, Kier R.* 1994. CT of the Iliopsoas Compartment: Value in Differentiating Tumor, abscess and hematoma. *American Journal of Roentgenology* 162: 83-86
- Moore KL, Agur AMR, Dalley AF.* 2015. *Essential Clinical Anatomy.* 5th ed. Philadelphia: Wolters Kluwer. Pp 184, 326-30
- Rao RT, Vanishree KPS, Rao S.* 2008. Bilateral Variation of Iliacus Muscle and Splitting of Femoral Nerve. *Neuroanatomy* 7: 72-75
- Saadeh FA, Bergman RA.* 1985. An Aberrant psoas major muscle fascicle. *Anat Anz.* 160: 367-68
- Siinatamby CS.* 2011. *Last's Anatomy- Regional and Applied.* 12th ed. London: Elsevier. Pp 117-19
- Snell R.* 2012. *Clinical Anatomy by Regions.* 9th ed. Philadelphia: Wolters Kluwer. Pg. 463
- Spratt JD, Logan BM, Abrahams PH.* 1996. Variant Slips of Psoas and Iliacus Muscles, With Splitting of the Femoral Nerve. *Clin Anat* 9: 401-04

ACKNOWLEDGEMENTS

I would like to express my gratitude to the donor and donor's family for the incredible gift of body donation. Additionally, to the anatomy department at The University of Edinburgh for the space and resources; particularly to Mr Iain Cambell and Mrs Susan Bond for the technical support during dissection. Finally, I would like to thank Professor Andrés Limardo for translating the title and abstract for submission.