

Case Report

DOUBLE MIDDLE COLIC ARTERIES IN A FEMALE CADAVER OF ASIAN ORIGIN - A CASE REPORT

Chitra Ramasamy¹, Shakthi Kumaran Ramasamy²

¹Department of Anatomy, Siddhartha Medical College, Vijayawada, Andhra Pradesh, India

²Aarupadai Veedu Medical College, Puducherry, India

RESUMEN

Tener conocimiento de las variantes en el suministro vascular del tracto gastrointestinal es esencial, sobre todo en procesos quirúrgicos de mínimamente invasivos. Se describe la rara variante de la arteria cólica media doble – arteria principal cólica media derecha de la arteria mesentérica superior y arteria accesoria cólica media izquierda del tronco celíaco en un cadáver femenino durante la disección ante estudiantes universitarios. Una arteriografía selectiva preoperatoria es importante para determinar tales anomalías antes de realizar resecciones pancreáticas electivas.

Palabras clave: Arteria cólica media, tronco celíaco, arteria mesentérica superior, arteriografía, resección pancreática

ABSTRACT

Knowledge of variant vascular supply of the gastrointestinal tract is essential, especially in minimal access surgical procedures. We describe the rare variation of double middle colic arteries, the main right middle colic artery from the superior mesenteric artery and the accessory left middle colic artery from the celiac trunk in a female cadaver during dissection for undergraduate students. A pre-operative selective arteriogram is important to determine such anomalies prior to performing elective pancreatic resections

Key words: Middle colic artery, celiac trunk, superior mesenteric artery, arteriogram, pancreatic resection

INTRODUCTION

The middle colic artery arises from the superior mesenteric artery near the lower border of the pancreas, courses through the transverse meso-

colon to supply the transverse colon. The vessel branches at a variable distance (3–10 cm) from the colonic wall, anastomosing with the ascending branches of the right and left colic arteries to form the marginal artery of Drummond (Standring, 2005). Origin of the middle colic artery from the superior mesenteric artery is fairly constant at 78–99% (Garcia-Ruiz et al, 1996).

The present case describes a rare variation of the double middle colic arteries in a female cadaver of about 60 years old of Asian origin. A middle colic artery originated from the superior mesenteric artery and another middle colic artery took origin from the celiac trunk. An undetected anomalous course of the middle colic artery could potentially cause its injury during pancreatoduodenectomy or retro-pancreatic dissection resulting in the transverse colon ischemia.

MATERIAL AND METHODS

During routine educational dissection of abdomen region for the first year undergraduate students of the academic year 2007-2008 in our department of anatomy, this rare variation of double middle colic arteries was observed in a female cadaver of about 60 years old of Asian origin. The arteries of the abdomen region were dissected following the standard dissection procedures.

* Correspondence to: Dr. R. Chitra. Siddhartha Medical College, Vijayawada, Krishna district, Andhra Pradesh. India. vjwchitra@yahoo.co.in

Received: 29 March, 2015. Revised: 8 May, 2015. Accepted: 6 June, 2015.

RESULTS

In the female cadaver, the first middle colic artery (MCA-I) arose as a first branch of the superior mesenteric artery which gave a branch to the head of pancreas and then divided into two branches, the right and the left (Fig.1). The right branch of this middle colic artery (MCA-I) anastomosed with the upper branch of the right colic artery and supplied the hepatic flexure and right one third of the transverse colon. In the same cadaver, the celiac trunk had four branches, the left gastric artery, the common hepatic artery, the splenic artery and the second

middle colic artery (MCA-II) (Fig.2). The middle colic artery originating from the celiac trunk passed behind the body of pancreas and then divided into right and left branches. The right branch of the MCA-II anastomosed with the left branch of MCA-I and supplied the middle one third of transverse colon. The left branch of MCA-II supplied the splenic flexure and upper part of the descending colon by anastomosing with the branch of the left colic artery from the inferior mesenteric artery. In the present case thus, the middle and left parts of the transverse colon and upper part of the descending colon had a vascular contribution from the celiac trunk

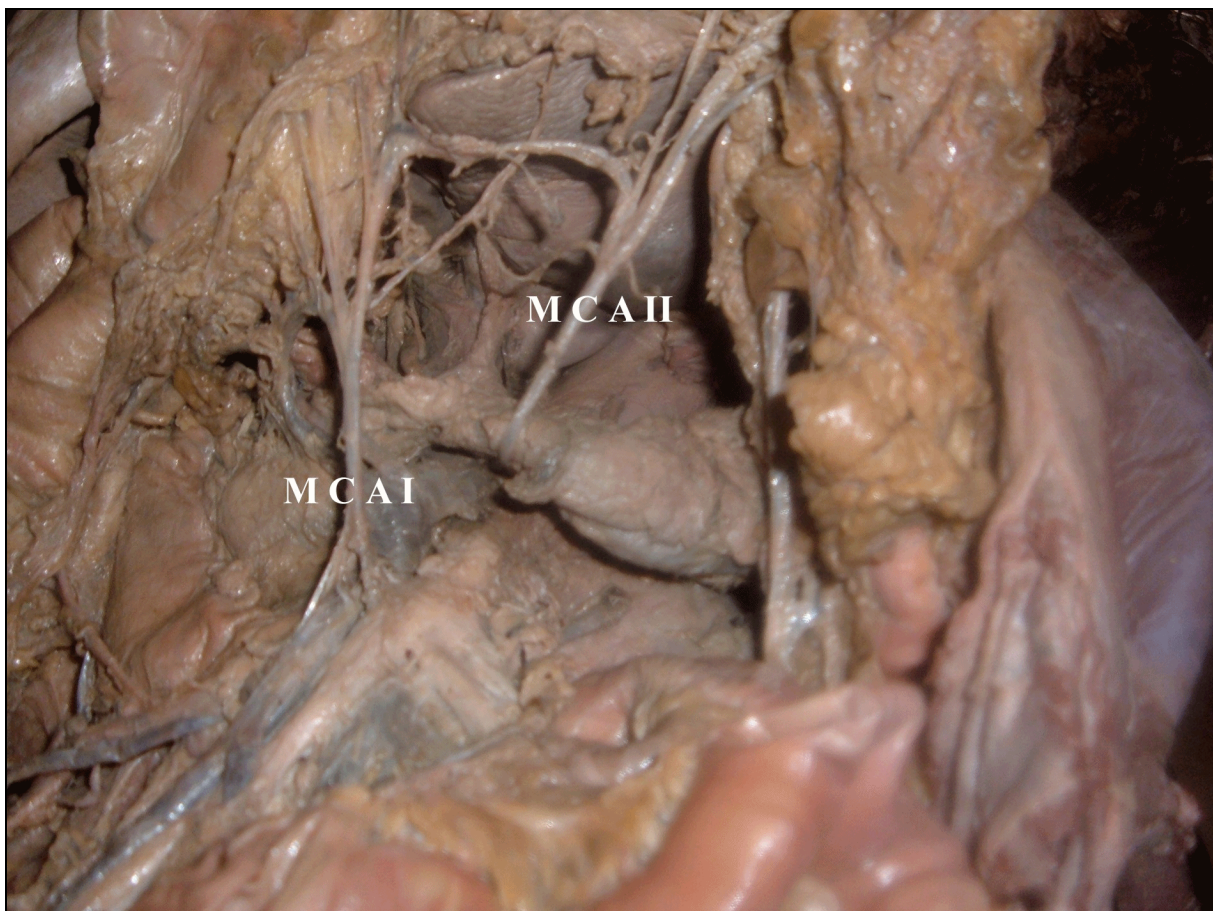


Figure 1: Showing double middle colic arteries, MCA I: Middle colic artery from the superior mesenteric artery, MCA II: Middle colic artery from the celiac trunk passing behind the neck of pancreas.

DISCUSSION

Garcia-Ruiz et al (1996) reported double middle colic arteries in the study of large series of cadaveric dissections. Middle colic arteries originate from the celiac trunk at a rate of 0.5% to 1% (Makowski et al, 2000, Yildirim et al, 2004;

Michels et al, 1965). A middle colic artery originating from the celiac trunk was considered as evidence for the ventral longitudinal anastomosis of the primitive vitelline arteries in the embryo (Tandler, 1904). Middle colic arteries arising from the splenic trunk (Amonoo-Kuofi et al, 1995; Murokami et al, 1998) or from hepatic

artery (Shoumura et al, 1991; Wadhwa and Barua, 2008) have been reported. Anomalous origin of the middle mesenteric artery from the aorta instead of the middle colic artery was reported by Yoshida et al (1993).

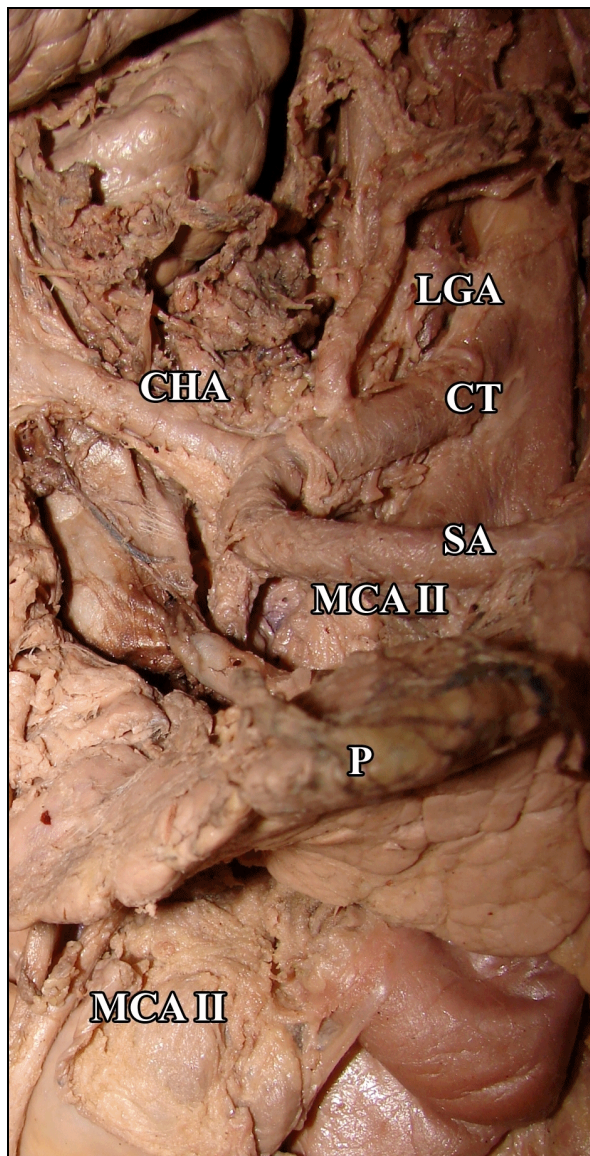


Figure 2: Origin of the middle colic artery from the celiac trunk, CT: Celiac trunk, CHA: Common hepatic artery, SA: Splenic artery, LGA: Left gastric artery, MCA II: Middle colic artery from the celiac trunk, P: Pancreas.

In the presence of the anomalous middle colic artery from the celiac trunk passing behind the body of pancreas, attention should be paid during the pancreatic resections and in the interposition of the transverse colon for esophageal replacement in order to avoid serious bleeding and necrosis. Retro pancreatic middle colic

arteries may spread the pancreatic malignancy to the transverse colon necessitating the resection of the transverse colon. Presence of an anomalous middle colic artery would need a higher level of lymph node dissection during transverse colonic resection for malignancy. These arterial variations need to be investigated by vascular studies prior to a major abdominal surgery.

Conflict of interest

None

Funding

None

Ethical approval

Not applicable

Informed consent

Not applicable

Contributions

Chitra Ramasamy - Identification of the anatomical variations in the particular cadaver and preparation of the manuscript. Shakthi Kumaran Ramasamy - Dissection of the arteries and capturing images of the arteries

REFERENCES

- Amonoo-Kuofi HS, el-Badawi MG, el-Naggar ME. 1995. Anomalous origins of colic arteries. *Clinical Anatomy* 8: 288–93.
- Garcia-Ruiz A, Milsom JW, Ludwig KA, Marchesa P. 1996. Right colonic arterial anatomy: Implications for laparoscopic surgery. *Diseases of Colon Rectum* 39: 906.
- Makowski M, Bartlewicz J, Krzanowski M, Nizankowski R, Szczeklik A. 2000. Atypical origin of the middle colic artery originating from the bed of CT. *Pol Arch.Med Wewn* 104: 859–62.
- Michels NA, Siddharth P, Kornblith PL, Parke WW. 1965. The variant blood supply to the descending colon, rectosigmoid and rectum based on 400 dissections: Its importance in regional dissections: A review of medical literature. *Diseases of Colon Rectum* 8: 51–278.
- Murokami T, Mabuchi M, Giuvarasteanu I, Kikuta A, Ohtsuka A. 1998. Coexistence of rare arteries in the human celiac mesenteric system. *Acta Med Okayama* 52: 239–44.
- Standing S. 2005. *Gray's Anatomy*. 39th edition. London: Elsevier Churchill Livingstone, 1193–94.

Shoumura S, Emura S, Utsumi M, Chen H, Hayakawa O, Yamahira T, Isono H. 1991. Anatomical study on the branches of the celiac trunk (IV): Comparison of the findings with Adachi's classification. *Kaibogaku Zasshi* 66: 452-61

Tandler J. 1904. Zur entwicklungsgeschichte des menschliden darmarterien. *Anat Hefte* 23: 475-99.

Wadhwa S, Barua MP. 2008. Anomalous middle colic artery originating from common hepatic artery: A Case Report. *Clinical Anatomy* 21: 796-99

Yildirim M, Celik HH, Yildiz Z, Tatar I, Aldur MM. 2004. The middle colic artery originating from

the coeliac trunk. *Folia Morphologica* 63: 363-65.

Yoshida T, Suzuki S, Sato T. 1993. Middle mesenteric artery: An anomalous origin of a middle colic artery. *Surgical Radiological Anatomy* 15: 361-63.

ACKNOWLEDGEMENT

I acknowledge the head of our department and institution for guidance and encouragement to prepare this manuscript.