

Original Communication**EVALUATION OF ACROMIAL GEOMETRY IN RELATION TO THE CUFF TEARS ON THIEL-EMBALMED CADAVERS USING 3D MICROSCRIBE DIGITIZER****Mohammad A. Alobaidy^{1,2}, Abdulrahman S. Alraddadi^{1,3}, Roger W. Soames¹**¹*Centre for Anatomy and Human Identification (CAHID), College of Art, Science and Engineering, University of Dundee, Dundee, UK.*²*Department of Anatomy, Faculty of Applied Medical Science, Umm Al-Qura University, Makkah, Kingdom of Saudi Arabia.*³*King Saud bin Abdulaziz University for Health Sciences, Riyadh, Saudi Arabia.***RESUMEN**

Objetivo: El propósito del presente estudio es evaluar la geometría del acromion en relación con las rupturas del manguito de los rotadores. Materiales y métodos: Se utilizaron 30 pares de escápulas, 20 del sexo femenino y 10 del sexo masculino, con una edad promedio de 82 años (con intervalo de 62 a 101 años). Las escápulas fueron escaneadas y las mediciones se realizaron con un digitalizador Microscribe 3D y el software de rinoceronte. Principales Resultados: La media encontrada para el ángulo de inclinación acromial y la vertiente fueron $38,70 \pm 5,91^\circ$ y $48,87 \pm 9,94^\circ$ respectivamente. La media de los ángulos acromial lateral y acromio-glenoideo fueron $81,13 \pm 8,72^\circ$ y $182,80 \pm 12,09^\circ$, respectivamente. Las distancias entre el acromial (la extremidad anterior y posterior) y el glenoideo fueron $28,7 \pm 3,77$ mm y $20,75 \pm 4,45$ mm, respectivamente. Los ángulos entre el acromion y la glena son más grandes en el lado izquierdo en comparación con el lado derecho, $186,49^\circ$ y $179,16^\circ$ ($P < 0,05$). La distancia entre el acromial posterior y el glenoideo mostró una diferencia significativa ($P < 0,05$) entre los sexos ($23,13$ mm para el sexo femenino y $26,37$ mm para el sexo masculino). Conclusión: No hubo diferencias significativas en relación a las roturas del manguito de los rotadores. La comprensión de la geometría del acromion es importante para mejorar las técnicas quirúrgicas en la cirugía del hombro.

Palabras clave: *acromion, geometría, digitalizador 3D Microscribe, cadáveres embalsamados con la técnica de Thiel.*

ABSTRACT

Objectives: The purpose of this study is to evaluate acromion geometry in relation to rotator cuff tears. Materials and Methods: Thirty pairs of scapulae from 20 females and 10 males, average age 82 years (range 62 to 101 years), were scanned and measurements taken using a 3D microscribe digitizer and Rhino software. Main Results: The mean angles of acromion tilt and slope were $38.70 \pm 5.91^\circ$ and $48.87 \pm 9.94^\circ$ respectively, while those for lateral acromial and acromial to glenoid were $81.13 \pm 8.72^\circ$ and $182.80 \pm 12.09^\circ$, respectively. The acromial (anterior and posterior tip) to glenoid distances were 28.7 ± 3.77 mm and 20.75 ± 4.45 mm, respectively. Left shoulders also were showed higher angles ($P < 0.05$) of the acromion to glenoid than right, 186.49° and 179.16° . Posterior acromial to glenoid distance showed a significant difference ($P < 0.05$) between females and males, 23.13 mm and 26.37 mm, respectively. Conclusion: There were no significant differences in relation to rotator cuff tears. Understanding the geometry of the acromion will improve surgical intervention in shoulder surgery.

Keywords: *Acromial geometry, rotator cuff tears, Thiel cadavers, 3D microscribe digitizer, and Rhino software.*

* Correspondence to: **Mohammad Alobaidy** Centre for Anatomy and Human Identification (CAHID), College of Art, Science and Engineering, University of Dundee, Dundee, DD1 5EH, UK. m.alobaidy@dundee.ac.uk.

Received: 1 April, 2015. **Revised:** 9 May, 2015. **Accepted:** 11 June, 2015.

INTRODUCTION

The scapula processes (acromion and coracoid) and the coracoacromial ligament form the coracoacromial arch above the subacromial space. The subacromial space contains the subacromial bursa, supraspinatus tendon and the long head of biceps tendon (Drake et al, 2005; Moore et al, 2010). The quadrilateral acromion is the expanded lateral end of the spine: it varies in size and shape (Bigliani et al, 1986). Rotator cuff muscles could be torn following trauma (i.e. after an accident) mostly affecting their tendons (Cooper and Ali, 2013). Rotator cuff tears are common and usually require surgical intervention, with the cause being degenerative changes or mechanical impingement due to acromion compression on the tendon (Hanciau et al, 2012). In 1931, Codman and Akerson suggested that tendon degenerative changes can lead to rotator cuff tears (Cooper and Ali, 2013;

Balke et al, 2013). Snyder (2003) classified rotator cuff tears morphologically into bursal tears, full-thickness tears and articular tears. Bursal partial tears have bursal-side fraying fibres, while full-thickness tears were limited to the supraspinatus tendon. Articular and intratendinous tears were excluded since they are not considered to be the result of bursal degenerative changes (Ozaki et al, 1988; Ko et al, 2008). Coracoacromial arch elements play an important role in rotator cuff tears, with changes in these elements affecting the dimensions of the coracoacromial space: narrowing of the space may lead to rotator cuff tears (Okoro et al, 2009). In order to evaluate the role of the acromion in the development of rotator cuff tears, further measurements of its geometry (including acromial tilt, acromial slope, lateral acromial angle, acromion to glenoid distance – both anterior and posterior tips) were determined.

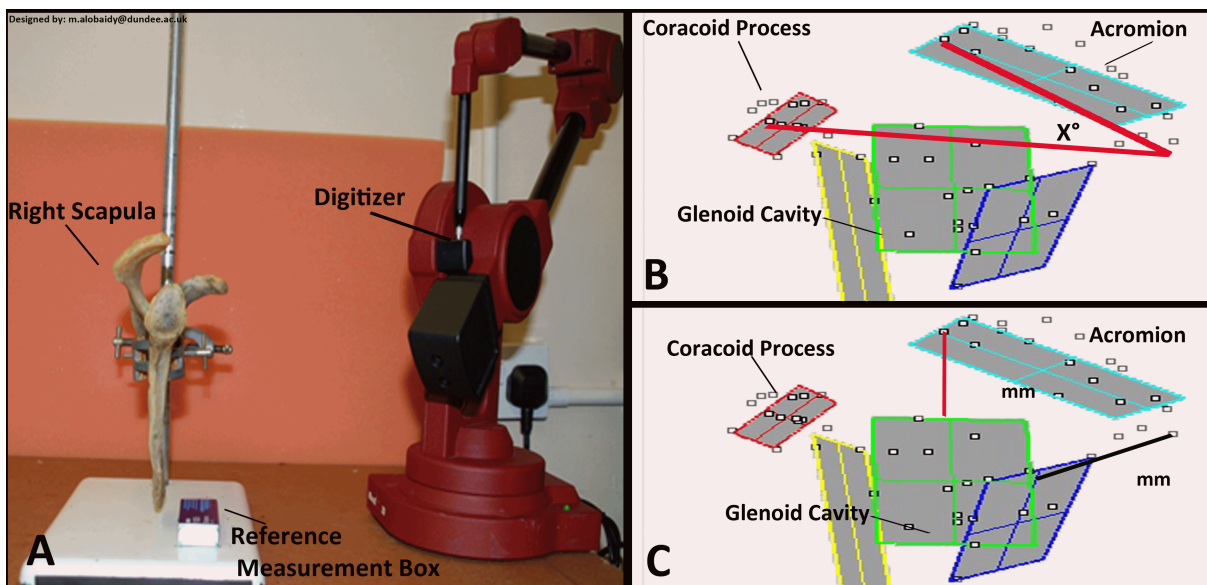


Figure 1- (A) The 3D microscribe digitizer, (Immersion Corporation, San Jose CA, USA) metallic holder on the 30x30 cm table and the 1 cm x 2 cm box. (B) The acromial tilt angle (X°) measurements. (C) The (anterior and posterior tip) acromial to glenoid fossa distance in millimetres (mm).

MATERIALS AND METHOD

Thirty pairs of scapulae from Thiel embalmed cadavers (20 females, 10 males) with an average age 82 years (range 62 to 101 years) were scanned and measurements taken using a 3D microscribe digitiser (Immersion Corporation, San Jose CA, USA) (Figure 1 (A)) and Rhino software (resolution 1000 μm), respectively. Rotator cuff

tears were noted during the dissection based on Snyder (2003) morphological classification into normal, bursal tear and full-thickness tear. Intraobserver and interobserver reliability tests were conducted to determine the accuracy and validity of the methodology; measurements were taken on a random selection of 3 specimens on three separate occasions by the same researcher for the intraobserver test, whereas the researcher

and two other individuals scanned and measured the same samples for the interobserver test. Measurements were taken by directly touching specific bony points on the acromion using the 3D digitizer, with the data points being directly entered into the Rhino software. The data collected was analysed using SPSS version 16.0 on Windows 7. The mean, standard deviation and level of significance were determined for the male and female specimens. The level of significance was set at $p < 0.05$. The following measurements were obtained:

a) Acromial tilt (AT)

The tilt was measured according to Aoki et al (1986) and Kitay et al (1995). A line was drawn from the anterior inferior to the posterior inferior points of the acromion and another line from the posterior inferior point to the inferior tip of the coracoid process. These lines form an angle (X) as shown in (Figure 1 B).

b) Acromial-glenoid distance (AGD)

The distance was measured (mm) from the most anterior tip of the acromion process to the supraglenoid tubercle ((Figure 1C: red line) Mansur et al 2013; Avila et al 2008). The distance from the posterior tip of the acromial

process to the nearest point of the glenoid fossa cavity is shown in Figure 1C (Black line).

c) Lateral acromial angle (LAA)

The angle was measured according to Bigliani et al (1986) and Kitay et al (1995). A line was drawn from the anterior inferior to the posterior superior points of the acromion and another from the posterior inferior to the anterior superior points of the acromion. These lines intersect forming an angle (X) as seen in Figure 2 (A) (taken from Lee et al 2008).

d) Acromial slope (AS)

The slope was measured according to Bigliani et al (1986) and Kitay et al (1995). A line was drawn from the anterior inferior to the posterior superior points of the acromion and another from the posterior inferior to the anterior superior points of the acromion. Where these lines intersect an angle (Y) is formed as shown in Figure 2 (B).

e) Acromial-glenoid angle (AGA)

The acromial to glenoid angle was measured by drawing a line between the supraglenoid to the infraglenoid tubercles and another from the anterior point of the acromion to midway along the glenoid fossa. The intersection of these lines forms an angle (Z) shown in Figure 2 (C).

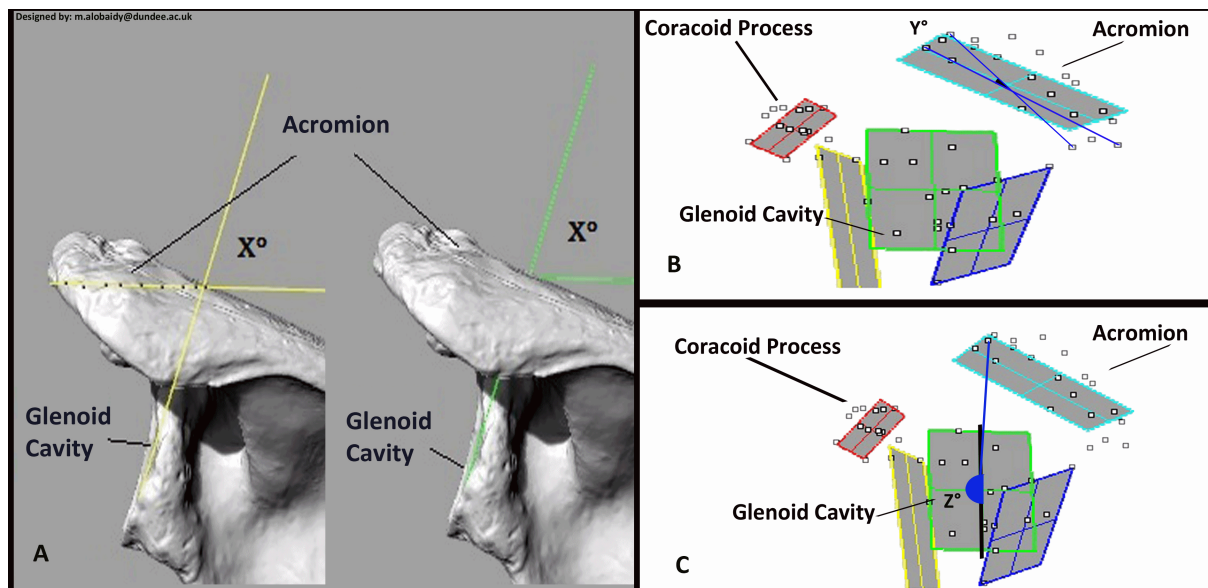


Figure 2- (A) The lateral acromial angle (X°) measurements. (B) The acromial slope angle (Y°) measurements. (C) The Acromial glenoid angle (Z°) measurements.

RESULTS

The intraobserver and interobserver reliability tests showed no significant difference between the measurements ($p \geq 0.05$). The means and

associated standard deviations, together with the range of values for each measurement with the corresponding values for the right and left scapulae are presented in Table 1. The values associated with males and females, and with and

without individuals with rotator cuff tears are shown separately in Table 2.

There was no significant difference between right and left sides, between males and females or between shoulders with and without rotator cuff tears for acromial tilt, acromion slope, lateral acromial angle or acromion (anterior tip) to glenoid distance. However, there was a significant difference ($P < 0.017$) between right

and left sides for the acromial to glenoid angle, but not between males and females or for shoulders with and without rotator cuff tears. In addition, a highly significant difference ($P < 0.002$) was observed between males and females for the acromion (posterior tip) to glenoid distance, but not between right and left sides or between shoulders with and without rotator cuff tears.

Measurement	Range	Mean \pm SD N= 60	Right side \pm SD N=30	Left side \pm SD N=30	P-value
(AT)	28-52°	38.7° \pm 5.91	39.76° \pm 6.17	37.67° \pm 5.52	0.17
(AS)	27-69°	48.87° \pm 9.94	50.11° \pm 10.03	47.64° \pm 10.05	0.34
(LAA)	63-106°	81.13° \pm 8.72	82.26° \pm 9.40	80.03° \pm 7.98	0.32
(AGA)	155.4- 209.8°	182.8° \pm 12.09	179.16° \pm 10.64	186.49° \pm 12.45	*0.017
(AAGD)	21.1-40.3 mm	28.7 mm \pm 3.77	29.29 mm \pm 4.11	28.25 mm \pm 3.39	0.29
(PAGD)	12-30 mm	20.75 mm \pm 4.45	20.77 mm \pm 4.52	20.73 mm \pm 4.46	0.97

Table 1- Descriptive statistics for 30 scapular pairs and the means and associated standard deviations of the angles and distances of the acromion on the right and left sides. *Abbreviation: Acromial tilt (AT), Acromial slope (AS), Lateral acromial angle (LAA), Acromial-glenoid angle (AGA), Anterior Acromial-glenoid distance (AAGD), Posterior Acromial-glenoid distance (PAGD) and Standard deviation (SD). Note: * $p \leq 0.05$, ** $p \leq 0.01$, and $p \leq 0.001$.

Measurement	Male \pm SD N=20	Female \pm SD N=40	P-value	Tears \pm SD N=33	No tears \pm SD N=27	P-value
(AT)	39.60° \pm 4.96	38.25° \pm 6.34	0.19	37.50° \pm 5.96	40.19° \pm 5.58	0.07
(AS)	47° \pm 8.92	49.73° \pm 10.41	0.16	49.64° \pm 9.04	47.93° \pm 11.23	0.51
(LAA)	81.90° \pm 8.95	80.75° \pm 8.69	0.42	82.31° \pm 8	79.72° \pm 89.48	0.25
(AGA)	179.30° \pm 11. 23	184.55° \pm 12.2	0.1	184.61° \pm 11.42	180.63° \pm 12.68	0.20
(AAGD)	36.14 mm \pm 4.06	28.35 mm \pm 3.90	0.51	29.13 mm \pm 3.67	28.35 mm \pm 3.91	0.41
(PAGD)	26.37 mm \pm 3.98	23.13 mm \pm 3.09	**0.002	19.87 mm \pm 3.90	21.84 mm \pm 4.90	0.08

Table 2- The means and associated standard deviations of the angles and distances of the acromion in males and females as well as for specimens with and without tears. *Abbreviation: Acromial tilt (AT), Acromial slope (AS), Lateral acromial angle (LAA), Acromial-glenoid angle (AGA), Anterior Acromial-glenoid distance (AAGD), Posterior Acromial-glenoid distance (PAGD) and Standard Deviation (SD). Note: * $p \leq 0.05$, ** $p \leq 0.01$, and $p \leq 0.001$.

DISCUSSION

The coracoacromial arch is considered to be the primary cause of rotator cuff tendon tears and rupture. However, aging, as well as other intrinsic and extrinsic factors, cause rotator cuff weakness and promote the progression of tendon tears (Ozaki et al 1988; Flatow et al 1994; Hanciau et al 2012). The data presented here were obtained directly from the scapulae using a 3D microscribe digitizer, whereas radiological studies, by their nature do not use direct measurement. In addition, the resolution of the scan/radiograph will influence the accuracy of the measurement taken.

The results of this study revealed that scapular measurements vary between males and females, as well as between the right and left sides and in individuals with and without rotator cuff tears. The parameters measured were acromial tilt, acromial slope, lateral acromial angle acromion to glenoid and acromial (anterior and posterior tip) to the glenoid fossa.

Balke et al (2013) measured the acromial tilt angle using a similar method as used in the present study and reported a mean angle for their control group of $29 \pm 5^\circ$ and for the group with impingement syndrome of $33 \pm 5^\circ$: the average age of their population was 49 years. The present study found the mean acromial tilt angle to be $38.7 \pm 5.91^\circ$ in a population of average age 82 years: this is higher than both the control and impingement groups of Balke et al (2013). The difference between the measurements was probably due to the method used in the present study. While the present study did not show a significant difference between individuals with rotator cuff tears and those without, the individuals with rotator cuff tears had lower acromial tilt angles ($p = 0.07$). Aoki et al (1986) and Kitay et al (1995) both state that the incidence of rotator cuff tears increases with lower angles of acromial tilt.

Avila et al (2008) and Mansur et al (2013) studied the anterior acromial to glenoid distance using MRI and cadaveric specimens, respectively. Their studies gave similar results (31.5 ± 5.5 mm), whereas Collipal et al (2010) and Singh et al (2013) reported smaller values (28.43 ± 2.7 mm). The present study is in agreement with previous studies. Since the present study confirmed the observations of the two previous studies of Avila et al (2008) and Mansur et al (2013), it suggests that the present method used and measurements taken are appropriate. However, Sitha et al (2004) and Paraskevas et al (2008) reported smaller values than the present study: although they used a similar method the measurement procedure was different. The

current study suggests that there is a significant difference between individuals with rotator cuff tears with respect to the acromial to glenoid geometry. Therefore, changes in the acromial to glenoid distance may affect the coracoacromial arch as well as leading to rotator tendon tears. In addition, Greene et al (2007), using 3D CT to measure the posterior acromial to glenoid distance, reported a value almost double that observed in the present study.

Using magnetic resonance imaging (MRI) Banas et al (1995) were the first to describe the method of determining lateral acromial angle, reporting it to be 78° (range $64^\circ - 99^\circ$). In the present study similar values were observed (81.1° : range $63^\circ = 106^\circ$). The agreement of findings is due to using the same protocol and the ease of accessibility to the area in the radiological studies and the 3D microscribe digitizer. In the present study, the lateral acromial angles were similar between right and left shoulders, males and females, and individuals with and without rotator cuff tears. However, Yu et al (2013), in an evaluation of 160 radiographs, found the mean lateral acromial angle to be 80° in healthy shoulders and 76.8° in shoulders with impingement syndrome. Hanciau et al (2012) concluded that 82.16% of their sample had an angle $<75^\circ$ which was significantly correlated with shoulder impingement. Moreover, Banas et al (1995) are of the view that the incidence of rotator cuff tears increase significantly with decreasing lateral acromial angle: this has been confirmed by Gu and Yu (2013). However, the present study showed that the mean angle in individuals with rotator tears was slightly, but not significantly, larger than those without. On the other hand, Mohamed and Abo-Sheisha (2014) evaluated the lateral acromial angle, based on the Lee et al (2008) method, and reported a mean lateral acromial angle of 75.8° for the control group and 69.75° for the patient group. This latter study presents results different to the present study; however this difference could be accounted for by the different measurement methods used and the mean ages of the populations studied.

Balke et al (2013) found the mean angle for the control and impingements groups to be $21 \pm 8^\circ$ and $25 \pm 11^\circ$, respectively, while Moor et al (2014), using the Aoki et al (1986) method of measuring the acromial slope, reported a mean angle in rotator cuff patients of 30.5° and for control patients 29° . Both studies evaluated the angle from radiographs. The present study could not confirm the findings of Balke et al (2013) or Moor et al (2014). It is possible that the mean age of individuals in the present and previous studies could account for this. The present study was undertaken according to the protocol of

Bigliani et al (1986) and Kitay et al (1995) using cadaveric samples evaluated using a 3D microscribe digitizer and Rhino software. The mean acromial slope in the present study was $48.9 \pm 9.94^\circ$, higher than some previous reports, nevertheless it agrees with Cho and Kang (1998), who reported a mean slope of $49.6 \pm 8^\circ$.

Greene et al (2007) measured the angle between the acromion and glenoid using computed tomography (CT), from which 3D models were reconstructed and analyzed using a Rapid-form 3D system. Their reported values were 52.9° for the whole sample, 52° for males and 53.7° for females, with no significant difference between them. In contrast, the present study revealed a mean acromial to glenoid angle of 182.80° , more than triple that of Greene et al (2007). There was a significant difference between the two studies, almost triple the value of the Greene et al measurements. In addition, there was a significant difference between left and right shoulders not reported by Greene et al (2007). Furthermore, females had large angles than males agreeing with Greene et al: individuals with rotator cuff tears also had large angles than those without. The measurement technique, sample size, ages of the sample and instrumentation used in this study may explain the differences in results between the present study and previous reports.

In conclusion, this is the first time that a 3D microscribe digitizer has been used to measure the geometry of the acromion process of the scapula. The study has clearly shown that a 3D microscribe digitizer and Rhino software can be used to determine the relationship between anatomical features of the scapula. In the present study, left shoulders had significantly higher acromial to glenoid angle than right shoulders. In addition, males had significantly higher acromial posterior tip to glenoid distances than females. Even though there were a significant number of individuals with rotator cuff tears, the present study showed only minor changes in the bony geometry.

Conflict of Interest

None of the authors have any conflict of interest with the material of this manuscript.

Funding

No funding or any financial support was received.

Ethical Approval

Not necessary

Informed Consent

Not necessary

Contributionship

Dissection, design, analysis and interpretation of data were done by Alobaidy M and Abdulrahman A. Drafting and critical revision were done by Alobaidy M. and Soames R. Supervised by Soames R.

REFERENCES

- Aoki M, Ishii S, Usui M. 1986. The slope of the acromion and rotator cuff impingement. *Orthop Trans* 10: 228.
- Avila M, Atencio E, Moreno F. 2008. Acromial findings associated with rotator cuff's lesions in Magnetic Resonance. *Rev Colom Radiol* 19: 2498-504.
- Balke M, Schmidt C, Dedy N, Banerjee M, Bouillon B, Liem D. 2013. Correlation of acromial morphology with impingement syndrome and rotator cuff tears. *Acta Orthop* 84: 178-83.
- Banas M, Miller R, Totterman S. 1995. Relationship between the lateral acromion angle and rotator cuff disease. *J Shoulder Elbow Surg* 4: 454-61.
- Bigliani LU, Morrison DS, April EW. 1986. The morphology of the acromion and its relationship to rotator cuff tears. *Orthop Trans* 10: 228.
- Cho B, Kang H. 1998. Articular facets of the coracoclavicular joint in Koreans. *Acta Anat*, 163: 56-62.
- Codman E, Akerson I. 1931. The pathology associated with rupture of the supraspinatus tendon. *Ann. Surg* 93: 348.
- Collipal E, Silva H, Ortega L, Epinoza E, Martínez C. 2010. The acromion and its different forms. *Int J Morphol* 28: 1189-92.
- Cooper A, Ali A. 2013. Rotator cuff tears. *Surg Oxford Int* 31: 168-71.
- Drake R, Vogl W, Mitchell A. 2005. *Gray's Anatomy for Students*. 1st ed. Philadelphia: Elsevier Churchill Livingstone, 671-73.
- Flatow E, Soslowky L, Ticker J, Pawluk R, Hepler M, Ark J, Mow V, Bigliani L. 1994. Excursion of the rotator cuff under the acromion patterns of subacromial contact. *Am J Sports Med* 22: 779-88.
- Greene A, Hamilton M, Jacobson A, Flurin P, Wright T, Zuckerman J, Roche C. 2007. Scapula Anatomy Study with Consideration to Reverse Shoulder Arthroplasty Biomechanics and Design. URL: <http://prgmobileapps.com/AppUpdates/ors/Abstracts/abs999.html> (accessed May 2014).
- Gu G, Yu M. 2013. Imaging features and clinical significance of the acromion morphological variations. *J Nov Physiother* S 2: 2.

- Hanciau F, Silva M, Martins F, Ogliari A.* 2012. Association clinical-radiographic of the acromion index and the lateral acromion angle. *Rev Bras Ortop* 47: 730-35.
- Kitay G, Iannotti J, Williams G, Haygood T, Kneeland B, Berlin J.* 1995. Roentgenographic assessment of acromial morphologic condition in rotator cuff impingement syndrome. *J Shoulder Elbow Surg* 4: 441-48.
- Ko S, Lee C, Friedman D, Park K, Warner J.* 2008. Arthroscopic single-row supraspinatus tendon repair with a modified mattress locking stitch: a prospective, randomized controlled comparison with a simple stitch. *Arthroscopy* 24: 1005-12.
- Lee K, Lee S, Jung S, Kim H, Ahn J, Kim K, Choy W.* 2008. The effect of the acromion shape on rotator cuff tears. *J Korean Orthop Assoc* 43: 181-86.
- Mansur D, Khanal K, Haque M, Sharma K.* 2013. Morphometry of acromion process of human scapulae and its clinical importance amongst a Nepalese population. *Kathmandu Univ Med J* 10: 33-36.
- Mohamed R, Abo-Sheisha D.* 2014. Assessment of acromial morphology in association with rotator cuff tear using magnetic resonance imaging. *Egypt J Radiol Nucl Med* 45: 169-80.
- Moor B, Wieser K, Slankamenac K, Gerber C, Bouaicha S.* 2014. Relationship of individual scapular anatomy and degenerative rotator cuff tears. *J Shoulder Elbow Surg* 23: 536-41.
- Moore K, Dalley A, Agur A.* 2010. *Clinically Oriented Anatomy*. 6th edition, Philadelphia: Lippincott Williams and Wilkins, 798-800.
- Okoro T, Reddy V, Pimpelnarkar A.* 2009. Coracoid impingement syndrome: a literature review. *Curr Rev Musculoskelet Med* 2: 51-55.
- Ozaki J, Fujimoto S, Nakagawa Y, Masuhara K, Tamai S.* 1988. Tears of the rotator cuff of the shoulder associated with pathological changes in the acromion. *J Bone Joint Surg Am* 70: 1224-30.
- Paraskevas G, Tzaveas A, Papaziogas B, Kitsoulis P, Natsis K, Spanidou S.* 2008. Morphological parameters of the acromion. *Folia Morphol* 67: 255-60.
- Singh J, Pahuja K, Agarwal R.* 2013. Morphometric parameters of the acromion process in adult human scapulae. *Indian J Basic Appl Med Res* 2: 1165-70.
- Sitha P, Nopparatn S, Aporn C.* 2004. The Scapula: Osseous Dimensions and Gender Dimorphism in Thais. *Siriraj Hosp Gaz* 56: 356-65.
- Snyder S.* 2003. *Shoulder Arthroscopy*, Philadelphia: Lippincott Williams and Wilkins, 210-17.
- Yu M, Zhang W, Zhang D, Zhang X, Gu G.* 2013. An anthropometry study of the shoulder region in a Chinese population and its correlation with shoulder disease. *Int J Morphol* 31: 485-90.

ACKNOWLEDGEMENTS

With all respect to the people who donated their bodies for teaching and research, thanks to Centre for Anatomy and Human Identification (CAHID) for giving me the chance to do my study and to gain the experience in dissecting Thiel-embalmed cadavers. Also, many thanks to Umm Al-Qura University, Makkah, Saudi Arabia for supporting me to use their online resources.