

Case report**ANOMALOUS ORIGIN OF THE LEFT VERTEBRAL ARTERY****Divya Premchandran, Sampath Madhyastha***Department of Anatomy, Kasturba Medical College, Bejai Campus, Mangalore, Manipal University, India***RESUMEN**

Las variaciones de los principales vasos arteriales son de importancia clínica. La arteria vertebral (VA) normalmente surge de la arteria subclavia. El presente informe describe un origen anómalo de la arteria vertebral izquierda (LVA) desde el arco aórtico entre el origen de la subclavia izquierda y la arteria carótida común izquierda. Esta arteria cruzó superficialmente de medial a lateral el tronco simpático izquierdo. La VA izquierda y derecha entraban en los agujeros transversos de la quinta vértebra cervical. Aunque el origen anómalo de la VA es bien conocida, su origen y la entrada a través del foramen transversal y sus relaciones con tronco simpático son de importancia clínica y durante los procedimientos vasculares en la región de cabeza y cuello tales como los stent de arteria carótida o vertebral y las intervenciones intracraneales.

Palabras clave: arco de la aorta, cadena simpática cervical, variaciones

ABSTRACT

Variations of major arterial vessels are of clinical significance. The vertebral artery (VA) normally arises from the subclavian artery. The present report describes an anomalous origin of the left vertebral artery (LVA) from the aortic arch between the origin of the left subclavian and the left common carotid arteries. This artery was crossed superficially from medial to lateral by the left sympathetic trunk. The left and right VA entered the foramen on the transverse process of the fifth cervical vertebra. Though the anomalous origin of the VA is known, its origin and entry through the transverse foramen and its relations with sympathetic trunk are of importance during clinical and vascular procedures in the head and neck region

like carotid artery stents, VA stents and intracranial interventions.

Key words: aortic arch, cervical sympathetic chain, variations

INTRODUCTION

The great arteries of the thorax are known for their variations. Anomalous origin and distribution of the large aortic arch vessels can cause changes in cerebral hemodynamics that may lead to cerebral abnormalities (Bernardi and Denton 1975). Knowledge of these variants is important to angiographers and vascular surgeons. This is essential in today's era of carotid artery stents, VA stents and therapeutic options for intracranial interventions (Poonam et al 2010).

The VA originates from the postero-superior aspect of the subclavian artery and passes through the foramen on the transverse processes of the upper six cervical vertebrae and enters the cranium through the foramen magnum. At the lower border of the pons it joins the contralateral to form the basilar artery (Standing, 2008).

* Correspondence to: **Sampath Madhyastha**. Department of Anatomy, Kasturba Medical College, Bejai Campus, Mangalore, Manipal University, INDIA, 575 004. sampath.m@manipal.edu

Received: 3 January, 2013. **Revised:** 20 January, 2013. **Accepted:** 22 February, 2013.

In angiographic and anatomic postmortem examinations, abnormal VA origins were reported as incidental findings (Lemke et al., 1999). These abnormalities are of diagnostic importance either prior to vascular surgery in the neck region or in cases of intravascular disease such as arteriovenous malformations, cerebral aneurysms,

arterial dissections and atherosclerosis (Lemke et al., 1999, Satti et al., 2007, Matula et al 1997). In the present case report, the anatomical topography of the variant VA observed was described with its morphological and clinical significance.

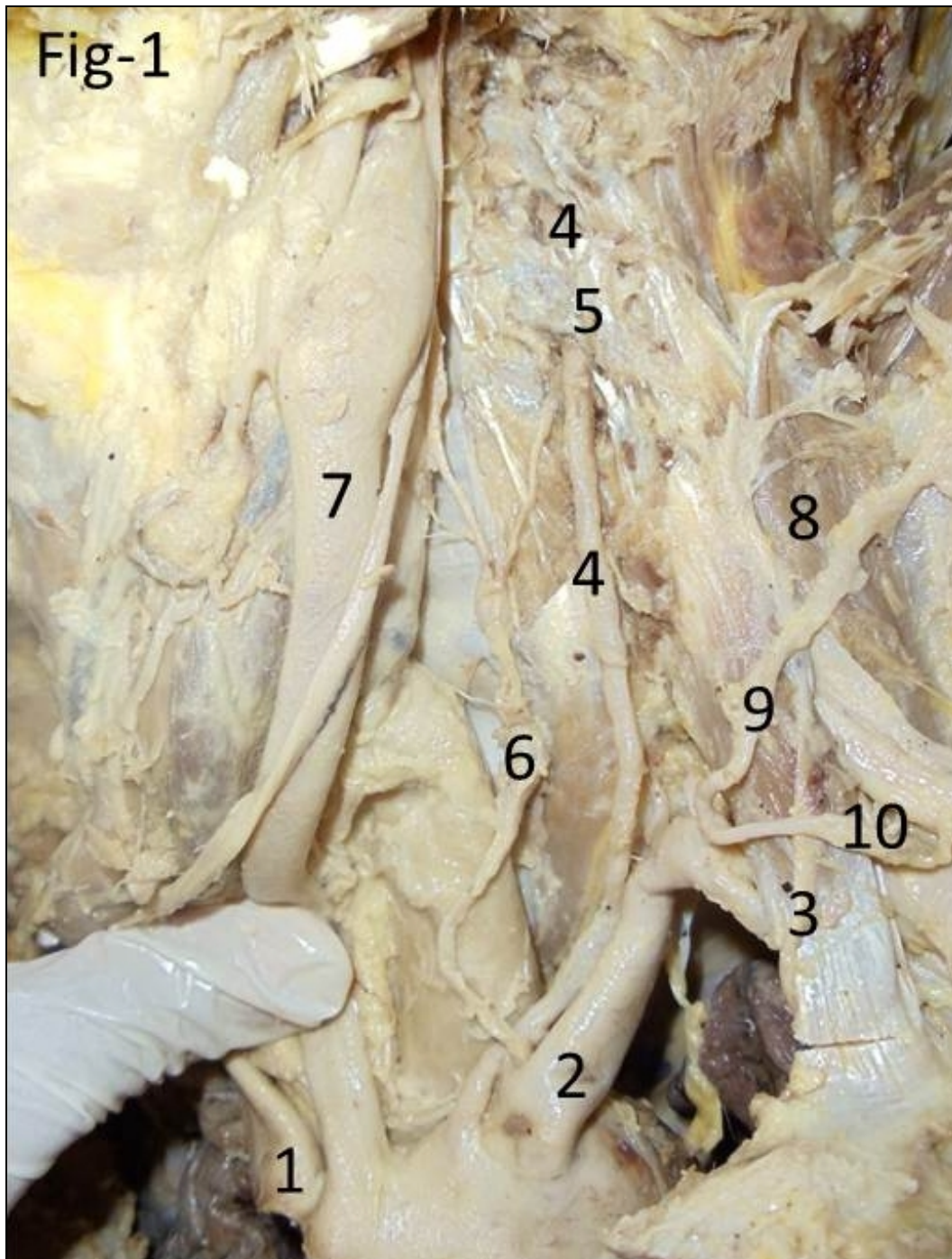


Figure1.- Vertebral artery on the left side.1 Brachiocephalic trunk. 2 Left subclavian artery. 3 Left phrenic nerve. 4 LVA. 5 Transverse Process of fifth cervical vertebra. 6 Left sympathetic chain. 7 Left common carotid artery. 8 Scalenus anterior muscle. 9 Transverse cervical artery. 10 Suprascapular artery.

MATERIALS AND METHODS

This variation was found during routine dissection of the head and neck region in a formalin preserved male cadaver of Caucasian origin about 70 years old conducted in the Department of Anatomy, Kasturba Medical College, Mangalore. The history of the individual and the cause of the death are unknown. The dissection of the neck was performed as per the Cunningham's manual of practical anatomy

(Romanes, 2005). The sternocleidomastoid muscle was cut to gain access to the scaleno vertebral triangle. The origin of the VA was located and its course was traced. Variation in the origin of the left vertebral artery (LVA) and a bilateral variation in the course of the VA were noted. The diameters of the two arteries were measured at the origin with digital Vernier callipers (in millimetres [mm]). The length of the arteries was measured with a thread and Vernier callipers (in mm).

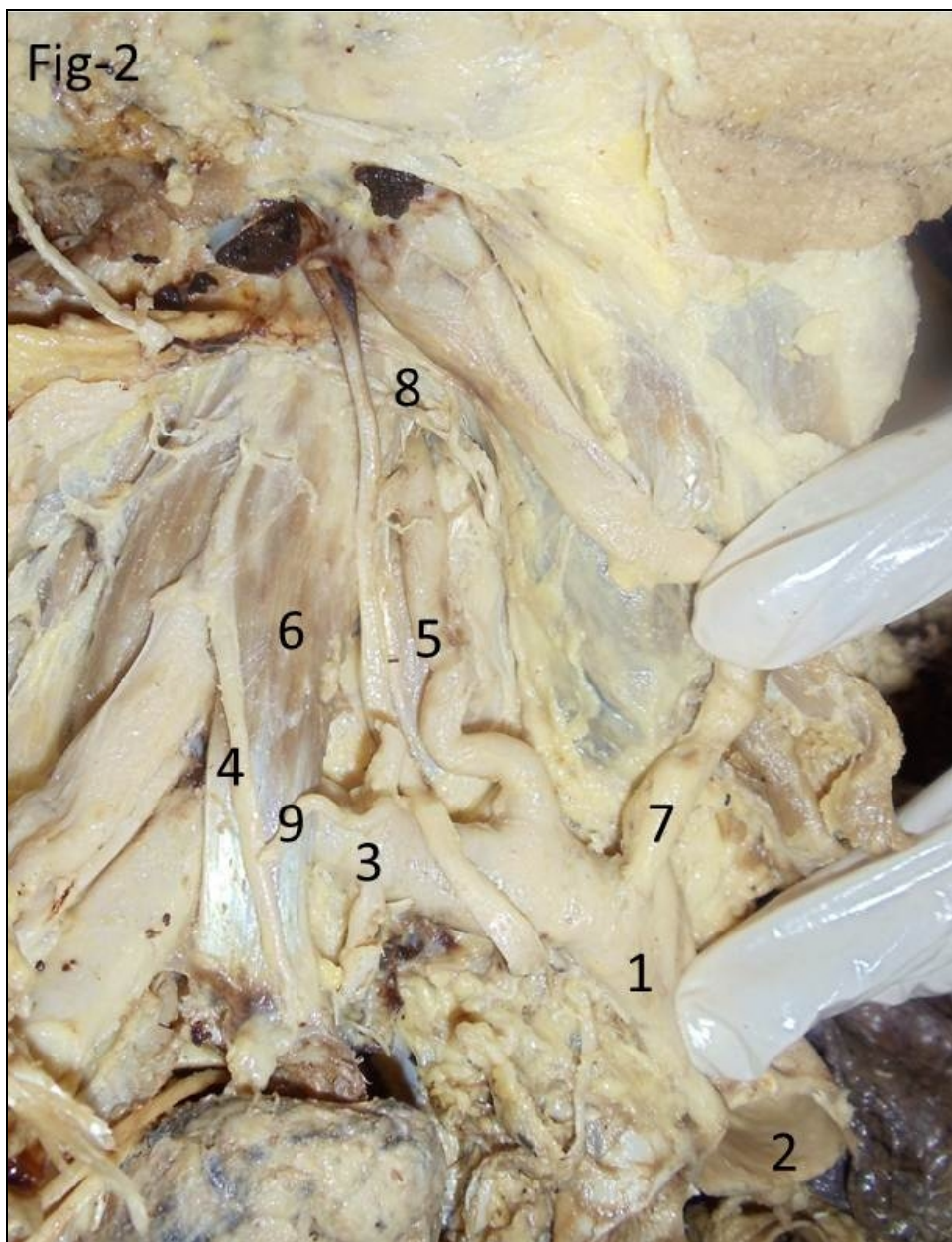


Figure 2.- Vertebral artery on right side. 1 Brachiocephalic trunk. 2 Aortic arch. 3 Right subclavian artery. 4 Right phrenic nerve. 5 Right VA. 6 Scalenus anterior muscle. 7 Right common carotid artery. 8 Transverse Process of fifth cervical vertebra. 9 Suprascapular artery.

RESULTS

The origin of right vertebral artery (RVA) and the LVA were noted. The LVA arose from the aortic arch between the left subclavian artery and the left common carotid artery (Fig.1). The origin of the RVA was normal. The diameter of the RVA at its origin was larger than the LVA measuring 13.8 mm while the LVA measured 8.4 mm (Fig.2). The length of the right and left VA from its origin to its point of entry through the foramen on the transverse process of the fifth cervical vertebrae was 54 mm and 88 mm respectively. The LVA was crossed superficially from medial to lateral side by the sympathetic trunk (Fig 1 and 3). The

trunk further descended posterior, to the subclavian artery. On both sides the VA entered the foramen of the transverse process of the fifth cervical vertebra. The VA did not have any branches in the scaleno-vertebral triangle. The branching pattern of the subclavian and the common carotid arteries were normal on both sides. The thyrocervical trunk divided into three branches. All three branches had a normal course. On the left side, the inferior thyroid artery was accidentally cut; the remaining two branches were labelled (Fig 1). On the right side, inferior thyroid artery and the transverse cervical branch were cut (Fig 2).

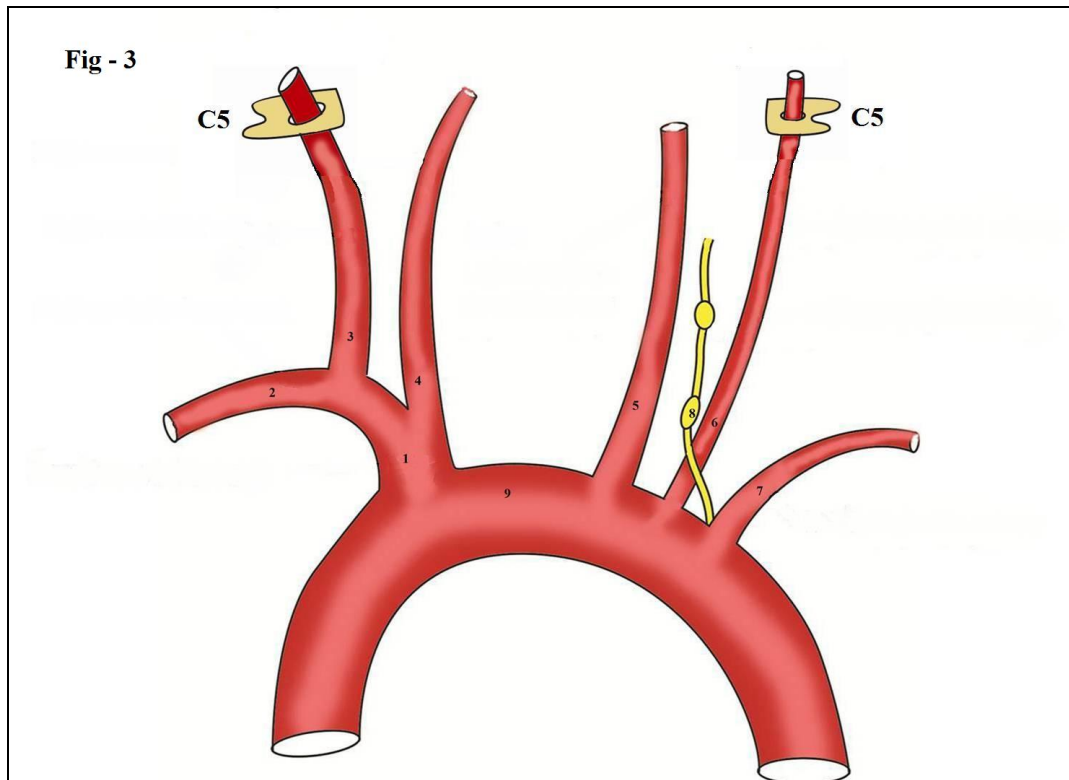


Figure 3.- Schematic representation of the variation. 1 Brachiocephalic trunk. 2 Right subclavian artery. 3 Right VA. 4 Right common carotid artery. 5 Left common carotid artery. 6 LVA. 7 Left subclavian artery. 8 Left sympathetic chain. 9 Aortic arch.

DISCUSSION

Anomalous origin of the VA from the aortic arch is well documented in literature. Previous studies conducted among Indian population showed a frequency of 7.4 to 8% wherein, the LVA originated from the aortic arch (Poonam et al, 2010 and Shiv Kumar et al., 2010).

An interesting observation in this report was that on both sides the VA entered the foramen on the transverse process of the fifth cervical vertebra. According to the Compendium of Human anatomic variation (Bergman, et al., 1988), the VA entered the sixth cervical vertebral foramen in 88% of the cases, the seventh cervical foramen in 5% and the fifth cervical vertebra in 7% of the

cases. A report by Rusu and Boscu (2010), also describes entry of VA through the transverse foramen of the fifth cervical vertebra.

It has been reported that both VA are usually unequal in size, the right being smaller than the left (Bergman et al., 1988). But in the present case, the diameter of the RVA was larger than the left.

It is established that the shear stress, is higher in VA arising from the aortic arch when compared to the subclavian origin. The VA of aortic origin receives direct arterial pulsatile flow whereas the VA of subclavian origin receives dampened blood flow due to presence of the subclavian artery proximally. Therefore VA of aortic origin has a greater predilection for arterial dissection. (Komiyama et al., 2001)

Anomalous origins may lead to altered haemodynamics and can predispose the patient to intracranial aneurysm formation. Therefore, in patients with these anomalies, a thorough search for coexisting aneurysms must be undertaken. Endovascular therapy of intracranial aneurysms can be performed before they present clinically as subarachnoid haemorrhages or as a mass effect and can decrease morbidity and mortality (Satti et al., 2007).

The most important benefit of detecting variations in the origin of the major arteries is diagnostic improvements before vascular surgeries (Patasi et al., 2009). A detailed knowledge of the anomalous origin of the major arteries is important in patients who have to undergo four vessel angiography. If a VA cannot be found in its original position, such a variation must be considered (Ligege and Scholtz 2004). This is the reason behind a routine angiography before catheterization of carotid or vertebral arteries.

The scaleno-vertebral triangle corresponds to the topographic triangle of the VA where the ganglionated sympathetic trunk and certain spinal nerves can be approached (Tubbs et al 2005). The altered topography within the scaleno-vertebral triangle may put the neurovascular structures at risk during various surgical approaches such as the anterolateral approach to the lower cervical spine (Civelek et al 2008).

The VA is a known constant landmark during cervical sympathetic block. The upper pole of the cervicothoracic ganglion was found to be located medial to the VA in 68.2% specimens in a study conducted by Kiray et al, 2005. In the present case report, the left sympathetic trunk was descending superficial to the LVA and deep to the subclavian artery.

Embryological basis: Developmentally the VA is a composite vessel and develops from the longitudinal anastomosis of the cervical segmental arteries. The first part of the artery is

developed from the dorsal part of the seventh inter-segmental artery (Datta AK 2010). In the present case, the left sixth dorsal inter-segmental artery might have persisted as the first part of the VA, and hence the LVA arose from the aortic arch.

In conclusion, though the anomalous origin of the VA has been reported in previous studies it is necessary to document this present variant with respect to its course and relations, which are of importance to head and neck surgeons.

REFERENCES

- Bergman RA, Thompson SA, Afifi AK and Saadeh FA.* 1988. The Compendium of Human Anatomic variation, Urban and Schwarzenberg, USA, 71-72
- Bernardi L, Denton P* 1975 Angiographic study of a rare anomalous origin of the vertebral artery. *Neuroradiology* 9:43-47
- Civelek E, Karasu A, Cansever T, Hepgul K, Kiris T, Sabanci A, Canbolat A.* 2008 Surgical anatomy of the cervical sympathetic trunk during anterolateral approach to cervical spine. *Eur Spine J*, 17: 991-995
- Datta AK.* 2010. Essentials of Human Embryology. 6th Ed. Current Books International, Kolkata, 183
- Matula C, Trattng S, Tschabitscher M, Day JD, Koos WT.* 1997 The course of the prevertebral segment of the vertebral artery, anatomy and clinical significance. *Surg Neurol*.48:125-31
- Kiray A, Arman C, Naderi S, Vencer M and Korman E.*2005. Surgical anatomy of the cervical sympathetic trunk. *Clinical Anatomy* 18:179-185
- Komiyama M, Morikawa T, Nakajima H, Nishikama M, Yasui T.* 2001. High Incidence of arterial dissection associated with left vertebral artery of aortic origin *Neurol Med Chir* 41: 8-12
- Lemke A, Benndorf G, Liebig T, and Felix R.* 1999. Anomalous origin of the right vertebral artery: Review of the literature and case report of right vertebral artery origin distal to the left subclavian artery. *Am J Neuroradiol* 20: 1318 – 1321
- Ligege P, Scholtz L Rare.* 2004. Variation in the origin of right vertebral artery. *SAJ of Radiol* 8: 34-35
- Patasi B, Yeung A, Goodwin S, Jalali A.* 2009. Anatomical variation of the origin of the left vertebral artery. *International Journal of Anatomical Variations* 2: 83-85
- Poonam, Singla RK, Sharma T.* 2010. Incidence of anomalous origins of vertebral artery – anatomical study and clinical significance.

- Journal of Clinical and Diagnostic Research 4: 2626-2631
- Romanes GJ.* 2005 Cunnigham's manual of practical anatomy. Vol 3 Head, Neck and brain 15th ed. Oxford: Oxford University Press, 65-80
- Rusu MC, Boşcu AL.* 2010 Transverse subisthmic course of the innominate artery in an adult: detailed anatomy and additional variation. *Folia Morphol (Warsz)* 69:261-6.
- Satti SR, Cerniglia CA, Koenigsberg RA.* 2007. Cervical vertebral artery variations: an anatomic study. *Am J Neuroradiol* 28:976-80
- Shiv Kumar GL, Pamidi N, Somayaji SN, Nayak S, Vollala V R.* 2010. Anomalous branching pattern of the aortic arch and its clinical applications. *Singapore Med J*, 51: 182
- Standing S.* 2008. In *Gray's Anatomy -The Anatomical Basis of Clinical Practice* 40 Ed, Churchill Livingstone, London, 449
- Tubbs RS, Salter EG, Wellons JC 3rd, Blount JP, Oakes WJ.* 2005 The triangle of the vertebral artery. *Neurosurgery*, 56: 252-255
- Yamaki K, Saga T, Hirata T, Sakino M, Nohno M, Kobayashi S, Hirao T.* 2006. Anatomical study of vertebral artery in Japanese adults. *Anat Sci Int* 8: 100-106.