

Case report**ORIGIN OF THE FACIAL ARTERY FROM THE LINGUAL-FACIAL TRUNK AND ITS COURSE THROUGH THE SUBMANDIBULAR SALIVARY GLAND: A CASE REPORT****Srinivasa Rao Sirasanagandla¹, Satheesha Nayak B¹, Bhagath Kumar Potu², Kumar MR Bhat³**¹*Department of Anatomy, Melaka Manipal Medical College (Manipal Campus), Manipal University, Manipal. Karnataka District. India*²*Department of Anatomy, School of medicine, UCSI University, Kuala Lumpur. Malaysia*³*Department of Anatomy, Kasturba Medical College, Manipal University, Manipal. Karnataka District. India***RESUMEN**

La disección cuidadosa del tercio posterior de la parte superficial de la glándula salival submandibular es uno de los pasos quirúrgicos esenciales en la extirpación endoscópica glandular, evitando daños en la arteria facial. Un buen conocimiento de la poco común relación entre la arteria facial y la glándula salival submandibular es de vital importancia para llevar a cabo de forma eficiente y segura la extirpación de la glándula submandibular. Las variaciones del patrón de ramificación de la arteria facial son bien conocidas y han sido expuestas en el pasado. Sin embargo, las variaciones en su origen y trayectoria son poco frecuentes. Durante una rutinaria disección de cabeza y cuello para los estudiantes universitarios de Medicina, observamos la inusual trayectoria de la arteria facial en el triángulo digástrico derecho en un cadáver de un varón de origen indio de aproximadamente 60 años. La arteria facial derecha se originó de la común lingual-facial del tronco por encima del nivel del asta mayor del hueso hioides, y luego atravesar a través de la sustancia de la parte superficial de la glándula submandibular, sin la formación de un bucle. Después la arteria entraba en la cara por el ángulo anteroinferior del masetero. A continuación, en su trayectoria intraglandular, esta arteria mostraba pequeñas ramificaciones glandulares.

Palabras clave: *arteria facial, tronco linguo-facial, glandular salival submandibular, triángulo digástrico.*

ABSTRACT

Careful dissection of the posterior one third of the superficial part of the submandibular salivary gland is

one of the essential surgical steps in endoscopic glandular excision, to avoid injury to the facial artery. A sound knowledge of unusual relationship of the facial artery with the submandibular salivary gland is essentially important to perform the safe and efficient submandibular gland excision. Different types of variations in the branching pattern of the facial artery have been reported in the past. However, variations in the origin and course of the facial artery are very rare. During the routine head and neck dissection for the medical undergraduate students, we observed an unusual course of the facial artery in the right digastric triangle of an approximately 60-year-old male cadaver of Indian origin. The right facial artery originated from the common lingual-facial trunk above the level of the greater horn of the hyoid bone, and then it traversed through the substance of superficial part of the submandibular salivary gland without forming a loop. Then this artery entered the face at the antero-inferior angle of the masseter. Further, in its intraglandular course this artery gave few small glandular branches.

Key words: *Facial artery, lingual-facial trunk, submandibular salivary gland, digastric triangle.*

* Correspondence to: **Dr. Kumar MR Bhat, PhD**, Associate Professor, Dept. of Anatomy, Kasturba Medical College, Manipal University, Manipal, India. kumar.mr@manipal.edu

Received: 31 January, 2012. **Revised:** 23 February, 2012. **Accepted:** 12 March, 2012.

INTRODUCTION

The blood supply to the face is provided mainly by the facial, transverse facial, and infraorbital arteries. Knowledge of the topographical anatomy of the lateral face, the standard and anatomical variations of these major arterial sources, are essential for performing the surgical and radiologic procedures in this area. In the last few years, articles clearly describing this have been published (Pinar et al., 2005; Tubbs et al., 2005a; Bratu et al., 2010; Yang and Lee, 2010; Yang et al., 2010; Crainiceanu and Matusz,

2011). Facial artery is the major artery of the face. It arises from the external carotid artery, above the lingual artery in the carotid triangle, just above the level of the greater horn of the hyoid bone. Then it runs upward and forward, deep to the posterior belly of the digastric and stylohyoid muscles before entering the digastric triangle. In the digastric triangle, it arches upward and medial to the ramus of the mandible and passes deep to the superficial part of submandibular gland making a characteristic loop, winding around the inferior border of the mandible.

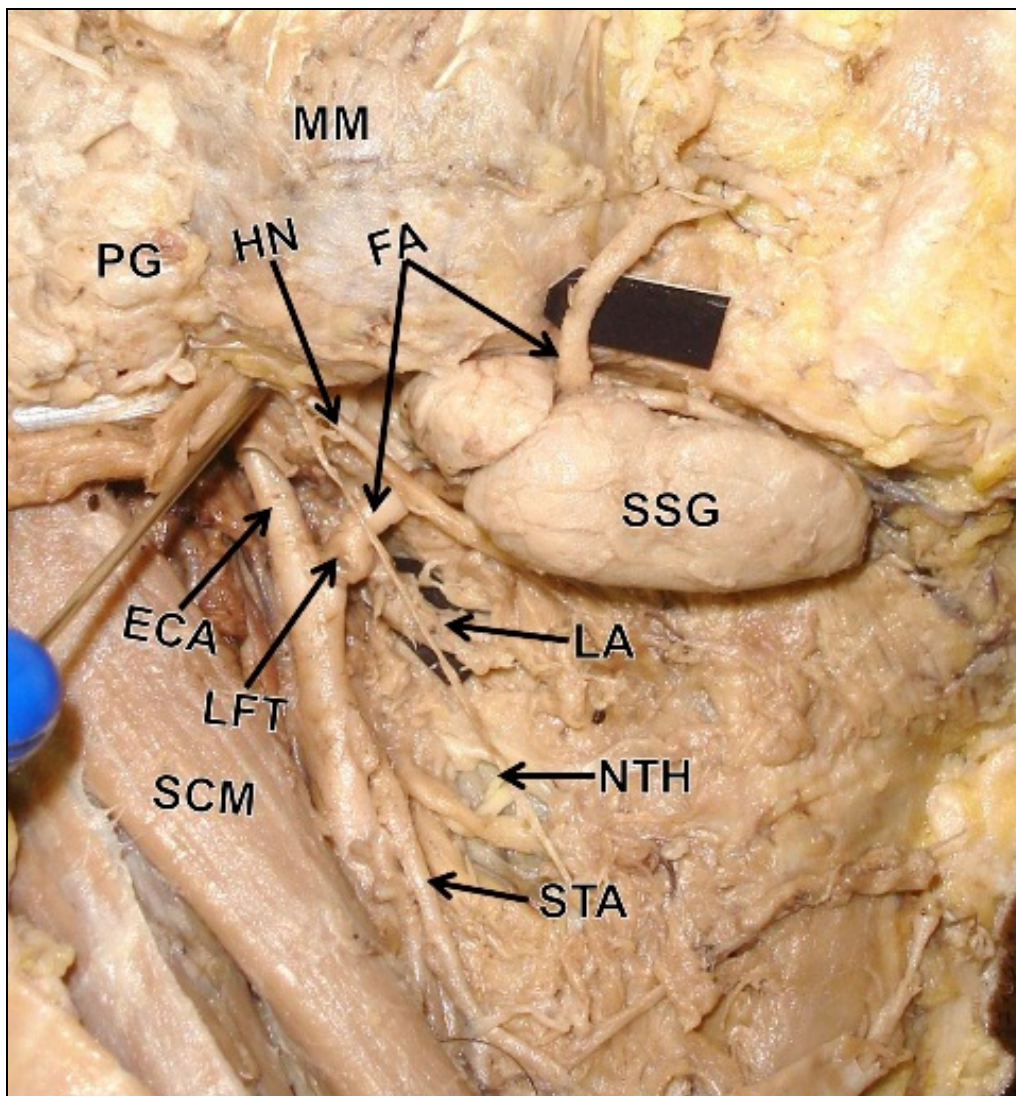


Figure1- Dissection of the right side of the neck and face, showing the unusual origin of the facial artery as a common lingual-facial trunk and its variant course through the superficial part of submandibular salivary gland. ECA- external carotid artery; LFT- lingual-facial trunk; FA- facial artery; LA- lingual artery; STA- superior thyroid artery; HN- hypoglossal nerve; NTH- nerve to thyrohyoid; SSG- superficial part of submandibular salivary gland; PG- parotid gland; SCM- sternocleidomastoid muscle; MM- masseter muscle

It then enters the face at the antero-inferior angle of the masseter after piercing the investing layer of the deep cervical fascia. In the face, it runs upward and forward with tortuous course, lateral to the angle of the mouth, and terminates near the medial palpebral commissure. The part of the

artery distal to its terminal branch is called as angular artery. Its branches in the neck include the ascending palatine, tonsillar, glandular branches to the submandibular gland and the submental artery (Standring et al., 2005).

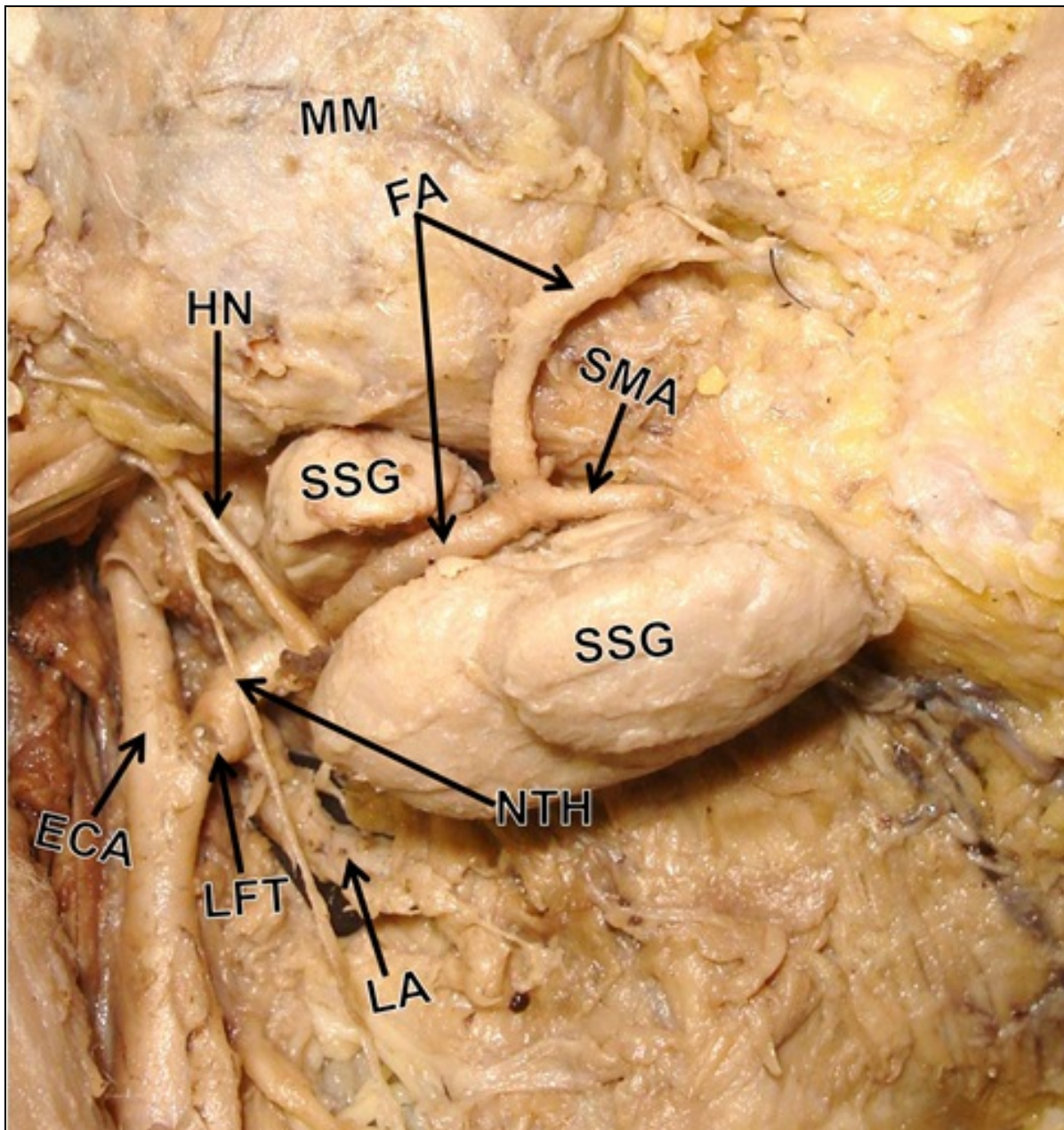


Figure 2- Closer view of the digastric triangle, showing the lingual-facial trunk and intraglandular course of the facial artery through the superficial part of the submandibular salivary gland. ECA- external carotid artery; LFT- lingual-facial trunk; FA- facial artery; LA- lingual artery; SMA- submental artery; HN- hypoglossal nerve; NTH- nerve to thyrohyoid; SSG- superficial part of submandibular salivary gland; MM- masseter muscle

CASE REPORT

During the dissection classes for the first year medical students, we found a rare variation in the origin and the course of the facial artery in the right digastric triangle of an approximately 60-year-old male cadaver of Indian origin. The dissection of this region was carried out according to the instructions by Cunningham's manual of practical anatomy (Romanes, 2004). In the present case, the facial artery was originated from the external carotid artery along with the lingual artery as a lingual-facial trunk, above the level of the greater horn of the hyoid bone in the carotid triangle. This lingual-facial trunk had very short course of 0.4 cm before dividing into lingual and facial arteries. Then, the facial artery had an upward and forward course deep to the posterior belly of the digastric muscle and then entered into digastric triangle. Further, the facial artery passed through the substance of the posterior end of the superficial part of the submandibular salivary gland and entered the face at the antero-inferior angle of the masseter without forming the classical loop in this region. Before entering into the submandibular gland, the facial artery was crossed by the hypoglossal nerve [XII]. After the dissection of the superficial part of the submandibular salivary gland, we found few small glandular branches from the intraglandular part of the facial artery (Fig.1 and Fig. 2). The course and the branching pattern of the facial artery in the face were found to be normal.

DISCUSSION

The anatomical characteristics and the variant patterns of the origin, course, termination and branches of the facial artery are essentially important to avoid complications in the maxillofacial surgeries, surgical interventions of the parotid and submandibular tumors and in the radiological investigations of the head and neck region. Although, the facial artery shows considerable variations in its branching pattern, the variations in its origin and course are rare. The lingual-facial trunk is commonly referred as anatomical variation of facial artery origin (Bergman et al., 1988). In a study conducted to evaluate the distribution of the external carotid artery trunks in the human fetuses, about 20% cases of lingual-facial trunk were observed (Zumre et al., 2008). Homze and his co-workers (1997) reported a frequency of the lingual-facial trunk in about 4% of their sample. A study

conducted by Fazan and his co-workers (2009) shows the differences in the occurrence rate of presence of the lingual-facial trunk (20% on the right side and 24% on the left side) in their samples. In their study, the average length of the lingual-facial trunk was 0.94 cm on the right and 0.76 cm on the left sides, before giving of the lingual and the facial arteries. However, in the present case, we report a very short lingual-facial trunk (0.4 cm). Since the erroneous interpretation and ligation of the lingual-facial trunk, could reduce the blood flow to the face, the knowledge of such variation is important when performing an extra-oral lingual artery ligation. Variations of this kind are of great importance in the radiological examinations and surgeries of the head and neck region.

Earlier, variations in the course, branching pattern and termination of the facial artery have been reported (Marx et al., 2008; Blair et al., 1962; Tubbs et al., 2005b; Bergman et al., 1988, Niranjana et al., 1988 and Loukas et al., 2006). Origin of the facial artery in the parotid region (Nayak, 2006) and in the digastric triangle (Mohandas et al., 2009) has been reported. Vary rarely, the facial artery may fail to form a characteristic loop on in its course (Marx et al., 2008). Few studies have reported the unusual origin of the glandular branches to the submandibular salivary gland. The glandular branches may arise from the external carotid artery (Mohandas et al., 2009 and Hiromitsu et al., 2011). Complete absence of the facial artery and glandular branches arising from the submental and lingual arteries to the submandibular salivary gland has been reported (Eid et al., 2011a). In the present case, we report a variant course of the facial artery through the substance of the superficial part of the submandibular salivary gland, and its entry to the face without forming a loop in the digastric triangle. In addition, contrary to previously reported variations, we report an unusual origin of glandular branches.

Presence of unusual glandular branches and variant intraglandular course of the facial artery, as reported here may be surgically important. Understanding of the variable blood supply to the submandibular gland is important to avoid complications in the surgical interventions for drooling (Eid et al., 2011b). As the submandibular gland is usually sacrificed in benign neoplasia, sialolith, sialoadenitis and plunging ranula, preservation of the facial artery may be important for reconstruction procedures of the head and neck. Therefore, profound knowledge about the unusual relationship of the facial artery and its glandular branches to the gland is important for

the radiologists, plastic and head and neck surgeons.

REFERENCES

- Bergman RA, Afifi AK, Miyauchi R.* 1988. Compendium of human anatomical variations. Baltimore: Urban and Schwarzenber, 65.
- Blair CBJ, Nandy K, Bourne GH.* 1962. Vascular anomalies of the face and neck. *Anat Rec.* 144: 251-257.
- Bratu T, Botti G, Matusz P.* 2010. A new perspective regarding the topographical anatomy of the transverse facial artery. *Clin Anat* 23: 460-461.
- Crainiceanu Z, Matusz P.* 2011. A new perspective regarding the topographical anatomy of the facial and transverse facial arteries. *Clin Anat* 24:921-923.
- Eid N, Ito Y, Otsuki Y.* 2011a. Anomalous branching pattern of external carotid artery: Clinical relevance to cervicofacial surgery. *Clin Anat* 24: 953-955.
- Eid N, Ito Y, Otsuki Y.* 2011b. Submandibular gland botulinum toxin injections for drooling: the safe and risky zones. *Surg Radiol Anat* 33: 465-466.
- Fazan VP, da Silva JH, Borges CT, Ribeiro RA, Caetano AG, Filho OA.* 2009. An anatomical study on the lingual-facial trunk. *Surg Radiol Anat* 31: 267-270.
- Hiromitsu E, Ryoichi M, Junji I, Naruhito O.* 2011. A case of completely absent facial artery. *International Journal of Anatomical Variations (IJAV)* 4: 72-74.
- Homze EJ, Harn SD, Bavitz BJ.* 1997. Extraoral ligation of the lingual artery, an anatomical study. *Oral Surg Oral Med Oral Pathol Oral Radiol Endod* 83: 321-324.
- Loukas M, Hullett J, Louis RGJ, Kapos T, Knight J, Nagy R, Marycz D.* 2006. A detailed observation of variations of the facial artery, with emphasis on the superior labial artery. *Surg Radiol Anat.* 28: 316-324.
- Marx C, Kumar P, Reddy S, Vollala VR.* 2008. Bilateral variation of facial artery: a case report. *Rom J Morphol Embryol* 49: 399-401.
- Mohandas Rao KG, Rodrigues V, Shajan K, Krishnasamy N, Radhakrishnan AM.* 2009. Unilateral high origin of facial artery associated with a variant origin of the glandular branch to the submandibular gland. *International Journal of Anatomical Variations (IJAV)* 2: 136-137.
- Nayak S.* 2006. Abnormal intra-parotid origin of the facial artery. *Saudi Med J.* 27: 1602.
- Niranjan NS.* 1988. An anatomical study of the facial artery. *Ann Plast Surg* 21: 14-22.
- Pinar YA, Bilge O, Govsa F.* 2005. Anatomic study of the blood supply of perioral region. *Clin Anat* 18: 330-339.
- Romanes GJ.* 2004. *Cunningham's Manual of Practical Anatomy.* 15th Ed. New York: Oxford University Press, 128-130.
- Standring S, Ellis H, Healy JC, Johnson D, Williams A, Collins P.* 2005. *Gray's Anatomy: The Anatomical Basis of Clinical Practice.* 39th Ed. London: Elsevier, Churchill Livingstone. 543-547.
- Tubbs RS, Kelly DR, Oakes WJ, Salter EG.* 2005a. Aneurysm of the distal facial artery from a penetrating oral prosthesis. *Clin Anat* 18: 527-529.
- Tubbs RS, Salter EG, Oakes WJ.* 2005b. Unilateral agenesis of the facial artery with compensation by giant transverse facial artery. *Folia Morphol (Warsz).* 64: 226-228.
- Yang HJ, Gil YC, Lee HY.* 2010. Topographical anatomy of the transverse facial artery. *Clin Anat* 23:168-178.
- Zumre O, Salbacak A, Cicekcibasi AE, Tuncer I, Seker M.* 2005. Investigation of the bifurcation level of the common carotid artery and variations of the branches of the external carotid artery in human fetuses. *Ann Anat.* 187: 361-369.