

Original communication**STUDY OF ACROMIAL MORPHOLOGY IN INDIAN POPULATION****Susmita Saha¹, Neelam Vasudeva¹, Shipra Paul², Virender Kumar Gautam³**¹ Department of Anatomy, Maulana Azad Medical College, New Delhi, India² Department of Anatomy, Lady Hardinge Medical College, New Delhi, India³ Department of Orthopedics, Maulana Azad Medical College, New Delhi, India**RESUMEN**

Objetivos: El propósito del estudio era evaluar la morfología de acromion adulto en la población India y correlacionar su asociación con varias patologías del hombro. Materiales y métodos: La evaluación morfológica fue realizada en 200 omóplatos secos adultos obtenidos del museo de osteología del Departamento de Anatomía, Maulana Azad Medical College, Nueva Delhi. Se calculó la altura del arco acromial, ángulo anterior y posterior del arco y su índice, usando el método objetivo de Getz et al (1996) para demarcar forma acromial. La presencia o la ausencia de entesofitos fue observada en la superficie inferior de la cara anterior del acromion. Resultados: 28% de los omóplatos fueron el acromion de tipo I, 67% fueron el tipo II y el 5% fueron el tipo III. La presencia de entesofitos en la superficie inferior de la cara anterior del acromion también fue estudiada; los entesofitos fueron observados en 3.5% en el tipo acromial I, 15.67% en el tipo II y el 40% en el proceso acromial de tipo III. Conclusiones: La asociación entre el síndrome subacromial de compresión y el tipo acromial está bien establecida. Les asistirá a los clínicos para decidir la modalidad del tratamiento: conservador o quirúrgico. Se debe tener en cuenta la asociación de entesofitos subacromiales con la morfología acromial y los desgarros del manguito rotador al interpretar opacidades en las radiografías.

Palabras clave: Síndrome subacromial de compresión – Proceso acromial - Entesofitos – Manguito rotador

ABSTRACT

Objectives: The purpose of the study was to assess the morphology of adult acromion processes in Indian population and correlate its association with various

shoulder pathologies. Materials and methods: Morphologic evaluation was conducted on 200 adult dry scapulae obtained from osteology museum of Department of Anatomy, Maulana Azad Medical College, New Delhi. The height of the acromial arch, anterior and posterior angle of arch and their ratio were measured by using objective method of Getz et al (1996) for determining acromial shape. Presence or absence of enthesophyte was noted on the undersurface of the anterior aspect of the acromion process. Results: 28% scapulae exhibited type I acromion, 67% exhibited type II and 5% exhibited type III. The presence of enthesophytes on the anterior undersurface of the acromion was also studied; enthesophytes were observed in 3.5% in type I acromion, 15.67% in type II and 40% in type III acromion process. Conclusions: Association between subacromial impingement syndrome and acromial type is well established. This will assist the clinicians in deciding the modality of treatment: conservative or operative. Association of subacromial enthesophytes with acromial morphology and rotator cuff tears should be borne in mind when interpreting opacities on radiographs.

Key words: Subacromial impingement syndrome – Acromion process – Enthesophytes – Rotator cuff

* Correspondence to: **Dr (Mrs) Neelam Vasudeva**, MBBS, MS. Department of Anatomy, Maulana Azad Medical College, Bahadur Shah Zafar Marg, New Delhi- 110002, India. neelamvasudeva@gmail.com

Received: 22 February, 2011. **Revised:** 26 March, 2011. **Accepted:** 29 April, 2011.

INTRODUCTION

Subacromial impingement syndrome is believed to be one of the common causes of shoulder pain; the association between acromial morphology, shoulder impingement and rotator cuff tear is well documented (Bigliani et al, 1997). Tears in the rotator cuff occur secondary to attrition as a result of friction with the undersurface of the acromion. Three different morphologic types of acromion process have been described as by Bigliani et al (1986): type I – flat, type II – curved, type III – hooked by visual observation. Getz et al (1996) categorized three types of acromion processes by objective evaluation and reported 22.8% type I; 68.5% type II and 8.6% type III acromion process. They have noticed a substantially higher prevalence of full – thickness tear of the rotator cuff has been noted in association with type III acromion. The morphology of acromion and its relations with the uppermost point of the glenoid and coracoid process is very important in the determination of height of subacromial space; any variations of these three structures can predispose to the impingement syndrome (Torres et al, 2007). Most of the authors (Hamilton et al, 1875; Bigliani et al, 1986; Satoshi et al, 1989; Epstein et al, 1993; Gill et al, 2002; Toivenon et al, 2005 and Natsis et al, 2007) described differences in the shape of the acromion and correlated morphology of acromion with impingement syndrome. The enthesophytes were first described as etiologic factors in subacromial impingement and associated tears of the rotator cuff by Neer (1972), who described them as “spurs and excrescences”, which protrude into the subacromial space. Studies by Robert et al, 1983; Aoki et al, 1986; Ogata et al, 1989; Gohlke et al, 1993; Nicholson et al, 1996; Tucker et al, 2004 and Natsis et al, 2007 observed presence of enthesophytes in dry scapulae and correlated their presence with rotator cuff pathology. Considering the increasing number of such cases, this study will facilitate the surgeons in assessment and management of rotator cuff pathologies.

MATERIALS AND METHODS

Measurements of angles of the acromial arch were done on 200 adult dry scapulae obtained from the osteology museum of Anatomy Department, MAMC, New Delhi. Measurement of the anterior and posterior angles of the acromial arch was done by a technique devised by Getz et al (1996). Each acromion process was traced

from its anterior margin to the posterior margin by keeping it on a flat surface. The height of the resultant curve (h) was recorded by scale in millimeter. The anterior (α) and posterior (β) angles of acromial arch were measured by goniometer to determine the acromial type (Figure 1). A measurement of height (h) 2 millimeter or less, was categorized as Type I acromion process. If the height of the arch was more than 2 millimeter, then the ratio of anterior and posterior angles (α/β) was calculated for each acromion process. A ratio of 1.5 or greater was used to determine a Type III acromion. All other acromions with ratio less than 1.5 were classified as Type II.

Acromion process was categorized on a morphometric basis as follows:

Type I: $h \leq 2$ mm;

Type II: $\alpha/\beta < 1.5$

Type III: $\alpha/\beta > 1.5$

The data was statistically analyzed using SPSS ver.12 software and was subjected to Chi square test. Presence or absence of enthesophyte on the undersurface of anterior aspect of acromion process was also noted.

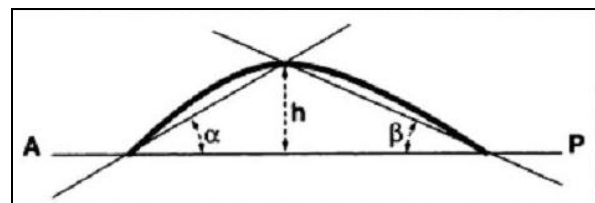


Figure 1: Method of acromial measurement. A: anterior margin of acromial arch, P: posterior margin of acromial arch, α : anterior acromial angle, β : posterior acromial angle, h : height of acromial arch and the heavy curved margin represents the undersurface of acromion

RESULTS

In our study, 200 dry scapulae were evaluated for the morphologic variations of acromion process. Among 200 scapulae, 91 were of right side and 109 of left side. By using objective method of Getz et al (1996) for determining acromial shape utilizing the height of the acromial arch, anterior and posterior angle of arch and their ratio, we obtained the following results: 56 scapulae exhibited type I acromion, 134 exhibited type II and 10 exhibited type III (Figure 2). The presence of enthesophyte when correlated with the type of acromion process demonstrated that, 2 out of 56

type I acromion had enthesophyte; out of 134 type II acromion 21 had enthesophyte and 4 out of 10 type III acromion had enthesophyte (Figure 3) on the anterior undersurface as shown in Table 1.

Chi square analysis revealed significant association between type III acromion and presence of enthesophytes ($p < 0.005$).

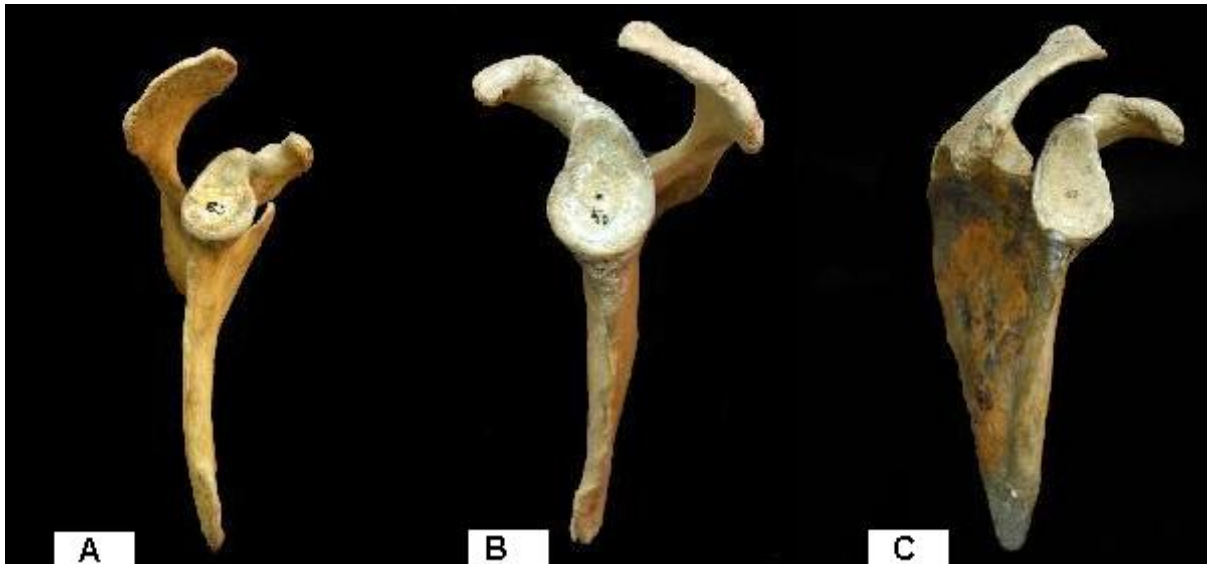

Figure 2: A) Lateral view of right scapula demonstrating type I (flat) acromion. B) Lateral view of left scapula demonstrating type II (curved) acromion. C) Lateral view of right scapula displaying type III (hooked) acromion.

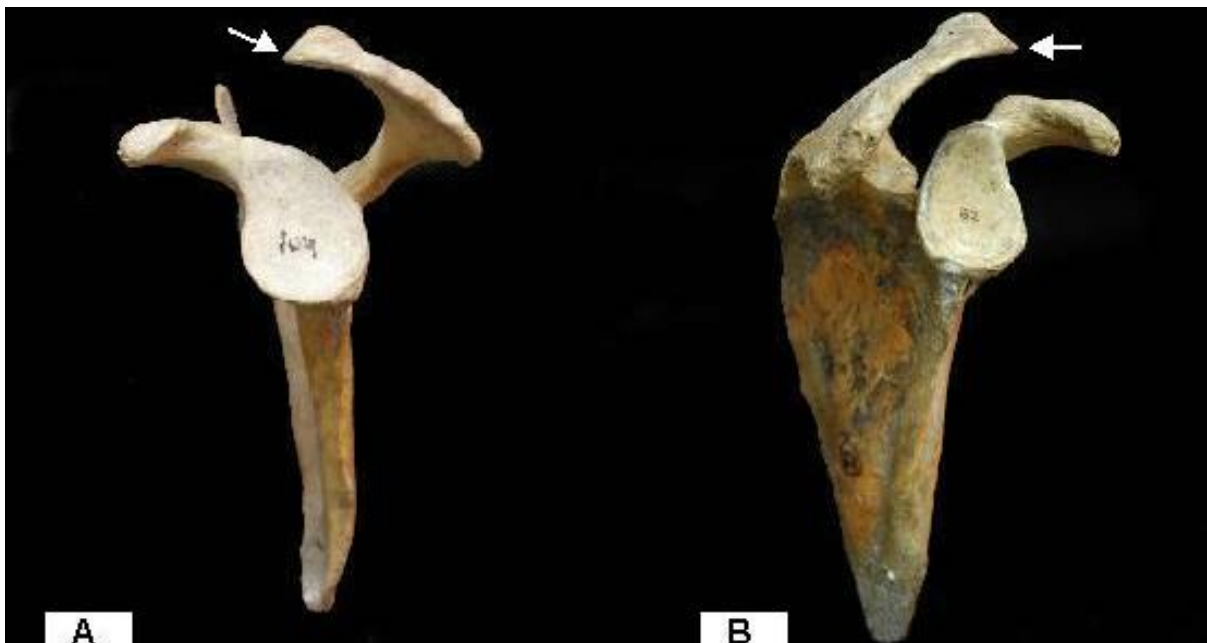

Figure 3: A) Lateral view of right scapula exhibiting type II acromion and enthesophyte at the anterior margin of acromion (arrow). B) Lateral view of right scapula exhibiting type III acromion and enthesophyte at the anterior margin of acromion (arrow).

Acromion type			Enthesophyte			
			Present		Absent	
Type		n	%	n	%	
I	Flat	56	2	3.57	54	96.4
II	Curved	134	21	15.67	113	84.32
III	Hooked	10	4	40	6	60
Total		200	27	13.5	173	86.5

Table 1: Distribution of enthesophytes among different types of acromion.

DISCUSSION

Impingement of the rotator cuff beneath the coracoacromial arch has been recognized as one of the causes for chronic disability of the shoulder. The disappointing results of complete acromionectomy and lateral acromionectomy stimulated investigators to probe the undersurface of the acromion in the genesis of the impingement syndrome (Neer, 1972). Special attention to the acromial morphology revealed alterations attributable to mechanical impingement in many cases and the anterior lip and undersurface of the anterior third of acromion was invariably involved. At about 80 degrees of abduction, the critical area of the supraspinatus tendon passes beneath the acromio clavicular joint which in turn tilts with overhead elevation of the arm. With the joint in this position excrescences on the undersurface of the anterior margin of the acromion are likely to impinge on the rotator cuff (Neer, 1972). On objective evaluation by Getz et al (1996) method, we found that, acromion type I were 28%; type II were 67.0% and type III were 5%. The results of our study are similar to study of Yazici et al (1995), Getz et al (1996) and Shah et al (2001). They also observed a higher incidence of type II, followed by type I and a very low incidence of type III acromion as seen in our study. Our study differs from studies done by Bigliani et al (1986) and Natsis et al (2007). They observed a higher incidence of type II acromion; followed by type III

acromion and a very low incidence of type I acromion. In the Study done by Nigar et al (2006) on 90 dry scapulae among Turkish population revealed a higher incidence of type II acromion as in our study. Sangiampong et al (2007) reviewed 154 dried scapulae in Thai population and reported that the incidence of type II acromion were the most prevalent type among the Thais as in our study in Indian population. The clinician needs to be well versed with the diverse appearance of acromion on dry bones, so that he can interpret acromial morphology on radiographs and magnetic resonance imaging scans. Association between subacromial impingement syndrome and acromial type is well established. This will assist him in deciding the modality of treatment: conservative or operative. The subacromial enthesophyte formation appears to be related to acromial shape; these bony spurs which develop within the coracoacromial ligament on the undersurface of acromion can encroach on the rotator cuff tendons. Over time and with repeated use this can cause degenerative wear and tear of rotator cuff leading to a partial or complete tear of rotator cuff (Neer, 1972). In our study we found that of the 200 bones, 27 acromions displayed enthesophytes on their undersurface. Of these 27 bones, 2 acromions of type I, 21 of type II and 4 of type III exhibited enthesophytes. Neer (1972) noted characteristic enthesophytes on the

undersurface of the anterior end of acromial process, believed to be secondary to repeated impaction by the rotator cuff and humeral head. Therefore the presence of subacromial enthesophyte formation on plain radiographs has been emphasized as an important indicator of subacromial impingement syndrome. In our study we have seen that there was a higher incidence of enthesophytes in association with type III acromion. Our results differ from the study conducted by Getz et al (1996); in which there was a high incidence of enthesophytes among type II acromion. The correlation between the types of acromion and the presence of enthesophytes at its anterior undersurface was also recorded by Natsis et al (2007). They noticed that enthesophytes were significantly more common in type III acromions and this combination is particularly associated with impingement syndrome and rotator cuff tears. Association of subacromial enthesophytes with acromial morphology and rotator cuff tears should be borne in mind when interpreting opaque shadows on radiographs. The location and size of enthesophytes, acromial shape and rotator cuff status will aid the clinician to decide the type of surgery.

REFERENCES

- Aoki M, Ishii S, Usui M.* 1986. The slope of the acromion and rotator cuff impingement. *Orthop Trans* 10: 228.
- Arraya S, Supin C, Sajai S, Penake T, Suwarat W.* 2007. Acromial morphology of Thais in relation to gender and age: Study in scapular dried bone. *J Shoulder Elbow Surg* 90 (3): 502-7.
- Bigliani LU, Levine WN.* 1997. Current concept review – Subacromial impingement syndrome. *J Bone Joint Surg Am* 79: 1854 – 1868.
- Bigliani, Morrison DS, April DW.* 1986. The morphology of acromion and its relationship to rotator cuff tears. *Orthop Trans* 10: 228.
- Cone R, Resnick D, Danzig L.* 1983. Shoulder impingement syndrome: Radiographic evaluation. *Radiology* 150: 29-33.
- Epstein RE, Schweltzer ME, Frieman BG, Fenlin JM, Mitchell DG.* 1993. Hooked Acromion: Prevalence on MR Images of painful shoulder. *Radiology* 187: 479-81.
- Getz JD, Recht MP, Piraino DW, Schlis JP, Latimer BM, Jellema LM, Obuchoeski NA.* 1996. Acromial morphology: Relation to sex, age, symmetry and subacromial enthesophytes. *Radiology* 199: 737-42.
- Gill TJ, McIrvine E, Kocher MS, Homa K, Mair SD.* 2002. The relative importance of acromial morphology and age with respect to rotator cuff pathology. *J Shoulder Elbow Surg* 11: 327-30.
- Gohlke F, Barthel T, Gandofer A.* 1993. The influence of variations of the coracoacromial arch on the development of rotator cuff tears. *Arch Orthop Trauma Surg* 113: 28-32.
- Hamilton FH.* 1875. Fracture of the scapulas .In a practical treatise on fractures and dislocations. Ed.5 .Philadelphia, Henry C. Lea 209- 21.
- Natsis K, Tsikaras P, Totlis T, Gigis I, Skandlakis P, Appell H.J, Koebke J.* 2007. Correlation between the four types of Acromion and the existence of Enthesophytes: A study of 423 dried scapulas. *Clin Anat* 20: 267-72.
- Neer CS.* 1972. Anterior acromioplasty for the chronic impingement syndrome of the shoulder. *J Bone Joint Surg Am* 54: 41–50.
- Nicholson GP, Goodman DA, Flatow EL, Bigliani LU.* 1996. The acromion: Morphologic condition and age related changes. A study of 420 scapulas. *J Shoulder Elbow Surg* 5:1-11.
- Nigar C, Kamil K, Can C, Bahadir D, Muzaffer S.* 2006. Anatomical basics and variation of the scapula in Turkish adults. *J Shoulder Elbow Surg* 27(9): 1320-25.
- Ogata S, Uthoff HK.* 1989. Acromial enthesopathy and rotator cuff tear. *Clin Orthop Relat Res* 254: 39-48.
- Shah NN, Bayliss NC, Malcon.* 2001. A. Shape of the acromion: Congenital or acquired - A macroscopic study of acromion. *J Shoulder Elbow Surg* 10: 309-15.
- Torres CA, Riberio CS, Maux SXDA, Oliveria GCD, Neves MG, Salgado ARF.* 2007. Morphometry of acromion process and its clinical importance. *Int J Morphol* 25(1): 51-54.
- Tucker TJ, Synder SJ.* 2004. The keeled acromion: an aggressive acromial variant-a series of 20 patients with associated rotator cuff tears. *Arthroscopy* 20 (7): 744-53.
- Toivonen DA, Tuite MJ, Orwin JF.* 1995. Acromial structure and tears of the rotator cuff. *J Shoulder Elbow Surg* 4: 376-83.
- Yazici M, Gulman B.* 1995. Morphologic variants of acromion in neonatal cadavers. *J Pediatr Orthop* 15: 644- 47.